

New Approaches in Assessing the Clinical and Pathomorphological Aspects of Obstetric Pathology in the Structure of the Mother-Placenta-Fetus using Atomic Force Research

Tatyana V. Pavlova^{1*}, Vasilii A. Petrukhin², Anton N. Kaplin³, Elena S. Malyutina¹, Alina V. Selivanova^{1,4}, Lyudmila O. Zemlianskaia⁵

¹Belgorod State University, 85, Pobedy St., Belgorod, 308015, Russia

E-mail: pavlova@bsu.edu.ru

²State budget health care institution of the Moscow region "Moscow Regional Research Institute of Obstetrics and Gynecology", 22a, Pokrovka St, Moscow, 101000, Russia

³Kursk State Medical University, 3, Karl Marks St., Kursk, 305041, Russia

⁴City hospital №2, gynecological department, 46, Gubkin St., Belgorod, 308036, Russia

⁵Doctor Clinic LLC Fomina, 119, Preobrazhenskaya St., 308015, Belgorod, Russia

Article History:

Submitted: 08.03.2020

Revised: 19.04.2020

Accepted: 26.05.2020

ABSTRACT

The aim of the research is study of histological features of the placenta's and uterus' structure, erythrocytes in the mother-placenta-fetus system during pregnancy, occurring against the background of thyroid diseases, diabetes (type I and gestational), moderate and severe preeclampsia. 117 pregnant women were examined during the study: 65 were with pathology of the thyroid gland (TG); 27 with diabetes mellitus; 15 with preeclampsia and 10 were the control group. All women underwent ultrasound scanning on an Alokka-5500 apparatus, and each of them was determined the level of thyroid hormones and antibodies to the TG, as well as glucose. Tissue morphometric analysis was performed using the "Ntegra-Aura" device, atomic force image analysis using standard software NOVA and Image Analysis ("NT-MDT"). During the study of the placenta's and myometrium's vessels were identified different circulatory disorders. It was found that the area of the villi and vessels of the terminal placenta decreased in the sequence: gestational diabetes mellitus (GDM), the state of

euthyroidism in the mother with thyroid pathology, hypothyroidism, diffuse toxic goiter (DTG), preeclampsia and type I diabetes mellitus (DM I). A significant increase in deformed and prehemolytic forms of erythrocytes was revealed. It was found that in the mother-placenta-fetus structure with pathology of the TG, DM and preeclampsia, multiple structural changes in the villous tree's and myometrium's tissues are observed, as well as changes in anatomical and functional structure of erythrocytes, which together contribute to the progression of fetal hypoxia.

Keywords: atomic force microscopy, pregnancy, thyroid gland, diabetes mellitus.

Correspondence:

Tatyana V. Pavlova

Belgorod State University, 85, Pobedy St., Belgorod, 308015, Russia

E-mail: pavlova@bsu.edu.ru

DOI: [10.31838/srp.2020.6.05](https://doi.org/10.31838/srp.2020.6.05)

©Advanced Scientific Research. All rights reserved

INTRODUCTION

Among the many causes of the occurrence of complications during pregnancy, special attention is paid to the mother endocrinopathies, due to the fact that pregnancy is a factor in additional stimulation of the TG and pancreas [1,2]. Frequently encountered types of obstetric pathology (GDM and preeclampsia) also make a huge contribution to the development of pregnancy complications [3,4].

The study of the mother-placenta-fetus system using atomic force microscopy allows to study the surface topography of altered cells and their membranes at the nanoscopic level, reveal the structural features of tissues and the relief structure of erythrocytes, which often change with these diseases and lead to tissue respiration disorders [5-8].

In connection with the foregoing, the aim of the research became to study the structural features of the placenta's, umbilical cord's, uterus' tissues and erythrocytes of the mother-placenta-fetus system during pregnancy, proceeding against the background of thyroid diseases, DM I and GDM, moderate and severe preeclampsia.

MATERIAL AND METHODS

Examination, treatment and delivery of pregnant women was carried out at the Belgorod Regional Clinical Hospital of St. Joasaph (Belgorod) and the Moscow Regional Research Institute of Obstetrics and Gynecology (Moscow). Morphological and biochemical studies were performed at the Department of Pathology of the Medical Institute of Belgorod

State University, as well as at the Scientific-Educational and Innovation Center "Nanostructured Materials and Technologies" of Belgorod State University.

All pregnant women participating in the study was divided into several groups:

the 1st group - with thyroid diseases occurring with an euthyroid state (thyroid hypertrophy of 1-2 degrees, mixed goiter) - 25 cases;

the 2nd group - with thyroid diseases occurring with hypothyroidism (congenital and postoperative hypothyroidism, autoimmune thyroiditis) - 20 cases;

the 3rd group - with diffuse toxic goiter (DTG) - 20 cases;

the 4th group - with I type DM - 12 cases,

the 5th group - with GDM - 15 cases;

the 6th group - with preeclampsia: 10 - moderate, 5 - severe;

the 7th group - control - without endocrinopathy, pronounced somatic and obstetric pathology - 10 cases.

An obstetric history was studied in all women, as a result of which it was found that there was no concomitant extragenital pathology, with the exception of the established one. In addition to the obstetric examination, special methods were performed: research on the TG with an Alokka-5500 ultrasound machine, determination of the levels of free and total thyroxine, triiodothyronine, thyroid hormone and antithyroid-depth antibodies, as well as glucose levels, including those after exercise. A clinical study of new borns was also conducted.

After tissue collection and analysis stained with hemaxilin and eosin, the necessary blocks were selected, viewed, photographed, studied using morphometric analysis in the Ntegra-Aura device. The work is carried out in contact modes, as well as in a constant profile using cantilevers Si or SiN using an atmosphere of low vacuum. Further analysis and obtaining of the atomic image was carried out using the standard software NOVA and Image Analysis of “NT-MDT”.

Erythrocyte research was also performed: samples from a suspension of erythrocytes washed from plasma were placed on defatted glass for immunohistochemical analysis and then in a wet Ntegra-Aura chamber for scanning. This method reduces the time of research and allows to get scans of cells with high resolution, without disrupting their functions, shapes and sizes.

RESULTS AND DISCUSSION

In the study of umbilical cord, we focused on circulatory system. In groups 1-6, the predominantly marginal position of erythrocytes was observed. In groups 2-4, 6, stasis, sludge and hemolysis were more often determined. Inside the vessels, fibrin was detected in the form of threads and layers (more often with DM I). It was also recorded, mainly in the venous section, the presence of blood clots, with DTG, preeclampsia and DM I. In addition, erythrocyte diapedesis, characteristic of groups with hypothyroidism, GDM, DM I and DTG, was detected. It should be noted that in cases complicated by preeclampsia (especially in its severe form) or with this type of obstetric pathology without preeclampsia, circulatory disturbance was observed most clearly.

In DTG and DM I groups, the endothelial cells of the vessels had a larger scatter in size (from 0.2 to 0.8 μm), outgrowths of the plasmalemma, violation of the structure of joints and microrelief were often observed. The folds on their surface increased in size and due to this, they were close to each other (Fig. 1A).




Figure 1: Fragments of the umbilical cord (A) with nodular goiter. Fig. B - the placenta. Fig. B with mixed goiter in the mother in euthyroid state, Fig. B - with DTG.

Fig. A. The cells of the endothelium of the umbilical cord vessel are loosely interconnected. Alternative changes in individual cells.

The predominance of intermediate villi (B).

Atomic force microscopy. B - three-dimensional image, A - two-dimensional.

In the stem villi, the walls of large vessels were often thickened and sclerotic, the lumen narrowed (groups 3, 4, 6). Blood clots in vascular lumen were observed in 11% with GDM, 13% with euthyroidism, 16% with hypothyroidism, 17% with DM I, 18% with DTG and 20% with preeclampsia (higher in combination with DM I).

The vascular region free of erythrocytes, blood clots and fibrin decreased in the following sequence of groups: №1 ($35.6 \pm 3.7 \mu\text{m}$ at $28 \pm 2.4 \mu\text{m}$ in control), №5 (32.1 ± 2.6), №2 ($12.6 \pm 1.9 \mu\text{m}$), №4 ($11.2 \pm 1.4 \mu\text{m}$), №3 ($10.3 \pm 1.6 \mu\text{m}$), №6 ($9.3 \pm 1.5 \mu\text{m}$). The depth of location of vessels in group №1 was slightly different from the control ($39.8 \pm 4.6 \mu\text{m}$ and $36.1 \pm 3.4 \mu\text{m}$, respectively). A decrease in depth, indicating greater tortuosity of the vessels, was observed in group №2 ($7.9 \pm 2.3 \mu\text{m}$), №5 ($7.1 \pm 1.4 \mu\text{m}$), №3 ($6.8 \pm 1.2 \mu\text{m}$), №5 ($6.1 \pm 1.3 \mu\text{m}$), №6 ($5.7 \pm 1.9 \mu\text{m}$). In addition,

atrophic changes in endotheliocytes were observed in some of the studied fragments, sometimes even to completely smooth the edges. The average distance between the folds in the villi for thyroid pathology was: for euthyroidism $1.85 \pm 0.25 \mu\text{m}$, for hypothyroidism - $3.05 \pm 0.25 \mu\text{m}$, for DTG - $3.83 \pm 0.32 \mu\text{m}$ (control group - $1.14 \pm 0.23 \mu\text{m}$).

In the endothelial microstructure, cytoplasmic bridges and small porous deepening with blood clots and areas of necrosis are clearly manifested. On the periphery of the stem villi, areas with accumulations of small, often full-blooded vessels of a compensatory nature, were found.

It was revealed that the greatest difference in the stem villi's relief is observed with euthyroidism ($15.5 \pm 4.5 \mu\text{m}$) and this indicator is close to that in the control group - $14.3 \pm 6.5 \mu\text{m}$. But with hypothyroidism and DTG this indicator is less: $8.6 \pm 0.5 \mu\text{m}$ and $7.5 \pm 0.4 \mu\text{m}$, respectively (Table 1).

Table 1: Relief indices of villi in pregnant women with various types of extragenital and obstetric pathology, μm

Observation group	Types of villi, μm					
	Terminal			Stem		
	elevation difference inside the villi	vascular area	vascular depth	elevation difference inside the villi	vascular area	vascular depth
Euthyroid state	4.8±1.3*	4.3±0.4*	3.8±0.9	15.5±4.5	35.6±3.7*	39.8±4.6
Hypothyroid state	2.6±0.7*	1.2±0.4*	1.4±0.1*	8.6±0.5*	12.6±1.9*	7.9±2.3*
diffuse toxic goiter	2.3±0.6*	1.1±.3*	1.2±0.2*	7.5±0.4*	10.3±1.6*	6.8±1.2*
GDM	36.2±1.1	3.9±0.4	3.2±0.7*	10.3±6.5*	23.5±2.1*	32.1±2.5*
DMI	3.0±0.5	1.3±0.2*	2.0±0.2*	7.1±1.5*	16.3±2.1	7.1±1.4*
Preeclampsia moderate	3.4±1.3	4.2±0.7	4.0±0.5*	11.2±4.5*	33.1±3.5*	35.2±3.6*
Severe preeclampsia	3.0±1.1	4.8±0.6*	3.1±0.4*	16.5±3.5*	37.2±3.5*	32.1±1.5*
Control	3.2±1.6	3.9±0.7	4.1±0.8	14.3±6.5	28.5±2.4	36.1±3.4

Note. * - $p < 0.05$ when compared with the control group

In all groups, villi of the intermediate type prevailed with a decrease in the number of lateral branches and moderate stromal vascularization. Their length in the group with the euthyroid state was $460 \pm 36 \mu\text{m}$, with hypothyroidism - $690 \pm 48 \mu\text{m}$, with DTG - $720 \pm 55 \mu\text{m}$, GDM - $420 \pm 42 \mu\text{m}$, DM I - $730 \pm 95 \mu\text{m}$, preeclampsia - $710 \pm 101 \mu\text{m}$ (in the control - $300 \pm 30 \mu\text{m}$). The relief drop in all groups, respectively, was: $0.9 \pm 0.3 \mu\text{m}$, $0.7 \pm 0.1 \mu\text{m}$, $0.6 \pm 0.2 \mu\text{m}$, $0.8 \pm 0.4 \mu\text{m}$, $0.6 \pm 0.3 \mu\text{m}$, $0.6 \pm 0.3 \mu\text{m}$ (control - $0.7 \pm 0.2 \mu\text{m}$). The vast majority of vessels are full-blooded, with an area of $35.6 \pm 3.7 \mu\text{m}$, $23.6 \pm 3.2 \mu\text{m}$, $39.2 \pm 2.2 \mu\text{m}$, $30.1 \pm 3.1 \mu\text{m}$, $33.6 \pm 6, 1 \mu\text{m}$, $49.3 \pm 6.6 \mu\text{m}$, respectively (control - $28.7 \pm 2.4 \mu\text{m}$). Significant fragments of sclerotic tissue were found in the stroma of the villi.

In the research of terminal villi, the studied parameters (growth, vascular zone) were located in the following sequence: GDM, the state of euthyroidism in the mother with thyroid pathology, hypothyroidism, DTG, preeclampsia and DM I. When calculating the depth of the capillaries of the terminal section, the indicators primarily reflected their tortuosity and were distributed as follows: $3.8 \pm 0.9 \mu\text{m}$, $3.7 \pm 0.5 \mu\text{m}$, $1.4 \pm 0.1 \mu\text{m}$, $1.2 \pm 0.2 \mu\text{m}$, $3.6 \pm 0.5 \mu\text{m}$, $4.0 \pm 0.6 \mu\text{m}$, $4.3 \pm 0.9 \mu\text{m}$ ($4.1 \pm 0.8 \mu\text{m}$). With fetal hypotrophy and hypoxia, the number of loops in vessels decreased, destruction of erythrocytes and their active contact with villus endothelium were observed.

Particular attention was paid to study of erythrocytes' structure, both inside vessels of villous tree, and in the intervillous space (IVS). A significant decrease in discocytes was found: with euthyroidism - $76 \pm 1.5\%$, with hypothyroidism up to $67 \pm 1.9\%$, with DTG up to $65 \pm 1.3\%$, with GDM up to $70 \pm 4.5\%$, with DM I up to $60 \pm 3.8\%$, with preeclampsia

up to $63 \pm 3.3\%$ (in the control group - $85 \pm 1.6\%$). When mother combined endocrinopathy with preeclampsia, their number didn't exceed $53 \pm 2.3\%$. Using the cell profile, the depth of the erythrocyte depression was calculated: $0.29 \pm 0.04 \mu\text{m}$, $0.30 \pm 0.03 \mu\text{m}$, $0.25 \pm 0.04 \mu\text{m}$, $0.28 \pm 0.05 \mu\text{m}$, $0.20 \pm 0.02 \mu\text{m}$, $0.15 \pm 0.02 \mu\text{m}$, $0.10 \pm 0.01 \mu\text{m}$, ($0.38 \pm 0.05 \mu\text{m}$).

The change in erythrocyte size in most cases was represented by microcytes with a diameter of $5.5 \pm 0.5 \text{ nm}$ and a thickness of $1.95 \pm 0.4 \text{ nm}$. The average size of red blood cells in the villus tree is slightly smaller than in the IVS. Among the altered erythrocytes oval and elongated forms were often observed, it may be a result of a violation of the elasticity of the membranes and a violation of the passage of red blood cells through the microvasculature. Echinocytes were rarely observed. With endocrine and obstetric pathology, degenerative forms of erythrocytes appeared: acanthocytes, cells in the form of a "deflated ball," bubble cells and schistocytes. Most often, such prehemolytic forms were observed with eclampsia. Separate blood cells were connected with each other and endotheliocytes by cytoplasmic bridges and fibrin strands (most of all with DM I and preeclampsia), which contributed to stasis, sludging and thrombosis.

In women with euthyroidism, the configuration of the myometrial vessels didn't practically differ from the control group, but a change in their shape was detected during hypothyroidism, DTG, DM I and preeclampsia (Fig. 2). With maternal thyroid disease, endotheliocytes were flatter and thinner due to an increase in vascular area. The greatest changes in the folding of endotheliocytes were observed in groups with hypothyroidism, DTG, DM I and preeclampsia.

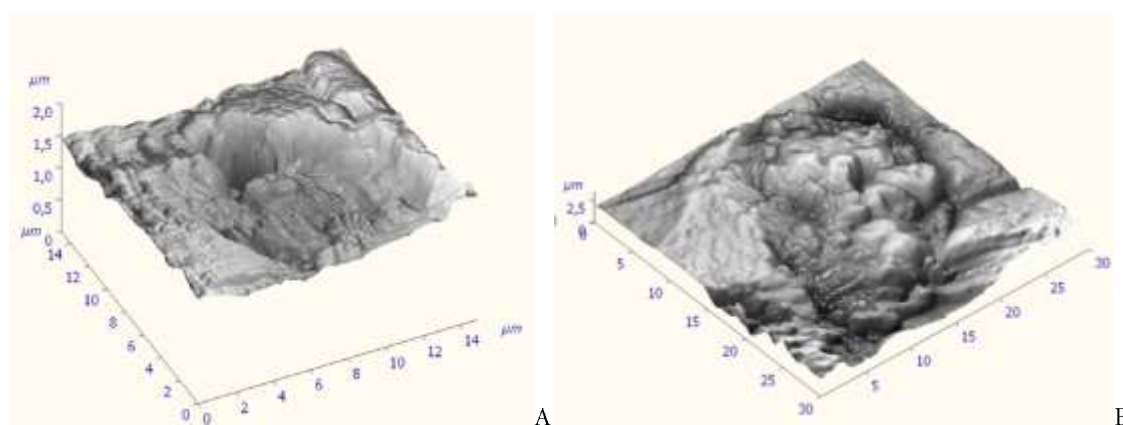


Figure 2: Fragment of the uterine myometrium of a woman with DTG.

Fig. A. The beginning of the formation of a blood clot in the spiral artery of the uterus.

Fig. B. Thrombus, clogging 80% of the vessel.

Atomic force microscopy. A, B - three-dimensional image.

The following changes were found in the vessels of the myometrium with pathology of the maternal TG. So, in women with a state of euthyroidism, the configuration of the vessels didn't practically differ from the control group, but with hypothyroidism, DTG, DM I and preeclampsia, a change in their shape was detected (Fig. 2). Endotheliocytes in all groups with maternal thyroid pathology were flatter and thinner than in the control group, mainly due to an increase in the area of blood vessels. The greatest changes in the folding of endotheliocytes were observed in groups with hypothyroidism, DTG, DM I and preeclampsia. In the vascular cavity, the same as in the placenta, variants of circulatory disorders were found. However, red blood cells are predominantly represented by spherocytes. It should be noted their pronounced stasis, sludge and thrombosis. In cases complicated by preeclampsia, plethora was observed most clearly.

In vessels of myometrium, changes in shape and structure of erythrocytes, their diapedesis were also noted; blood clots threads and layers of fibrin were detected in the venous section.

It was shown that the content of normocytes in the control group was within $84.30 \pm 1.41\%$ of the total number of discocytes. For all types of endocrine and obstetric pathologies, the number of reversibly altered, prehemolytic, and degenerative forms increased significantly (Fig. 3).

The ratio of the analyzed cells in size also changed. The most pronounced changes in size of erythrocytes are expressed in DM I (18.10 ± 1.50 microcytes and 14.0 ± 2.14 macrocytes) and DTG ($19.20 \pm 1.50\%$ and $15.10 \pm 2.51\%$, respectively), and with these pathologies there is the greatest increase in the number of macrocytes by relation to control group (Table.2). There is also an increase in the percentage of macrocytes in severe preeclampsia.

Table 2: The ratio of the size of erythrocytes in various types of obstetric and endocrine pathology

RBC ratio	Microcytes (%)	Normocytes(%)	Macrocytes (%)
Euthyroid state	$20.40 \pm 3.43^*$	$75.00 \pm 1.94^*$	$5.60 \pm 2.04^*$
Hypothyroid state	$22.60 \pm 1.49^*$	$78.50 \pm 1.9^*$	$7.40 \pm 0.14^*$
DTG	$19.20 \pm 1.50^*$	$65.70 \pm 2.31^*$	$15.10 \pm 2.51^*$
GDM	$18.20 \pm 1.41^*$	$75.50 \pm 1.25^*$	$6.30 \pm 0.14^*$
DMI	$18.10 \pm 1.50^*$	$67.70 \pm 2.31^*$	$14.20 \pm 2.14^*$
Preeclampsia moderate	$18.20 \pm 1.41^*$	$75.50 \pm 1.25^*$	$6.30 \pm 0.14^*$
Severe preeclampsia	$12.20 \pm 1.50^*$	$72.50 \pm 2.31^*$	$15.30 \pm 1.15^*$
Control	14.30 ± 1.52	84.30 ± 1.41	1.40 ± 0.14

Note. * - $p < 0.05$ when compared with the control group.

In all the studied groups, except the control one, in the vessels of the myometrium there was an uneven surface of erythrocytes, a violation of the structure of the cytoplasmic membranes, a change in the architectonics of their outgrowth, which is especially characteristic of DTG and DM I. When studying the depth of the cavity of discocytes, it was shown that it also didn't significantly differ from that in the vessels of the uterus. On the surface of the cells of the control

group, pores were observed, forming a pronounced uniform pattern, $0.61 \pm 0.15 \mu\text{m}$ in size with internal relief projections, which changes with different types of obstetric pathology (Fig.3). In the pathologies, on the cell surface regularly found round-shaped same type protrusions $0.28 \pm 0.08 \mu\text{m}$ wide. In their central areas, ridges located in parallel are also noted.

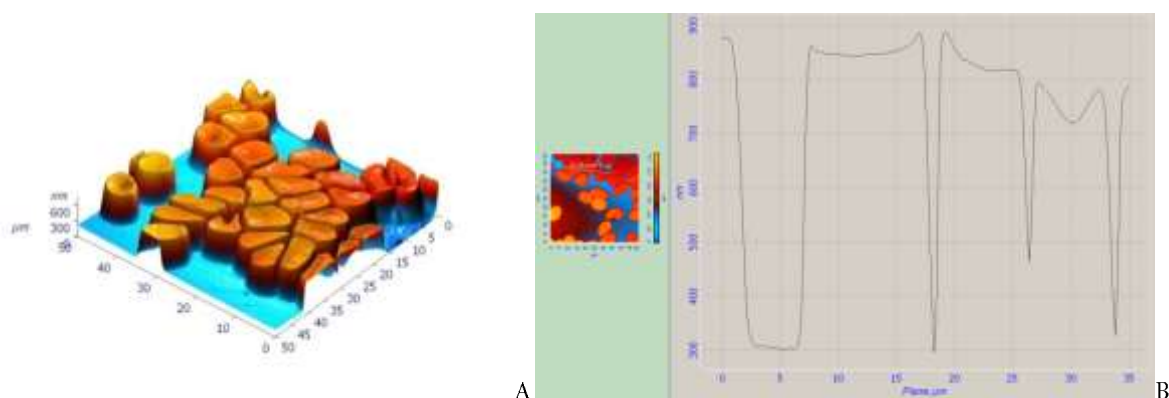


Figure 3: Red blood cells in pregnant women (A, B) with severe preeclampsia.

SURGE of red blood cells. The curvature and depth of the central depression are changed. Atomic force microscopy. A - three-dimensional image, B-graphic image.

CONCLUSION

Thus, the data revealed in the study of placental and myometrium tissue in thyroid pathology, diabetes (type I and gestational) and preeclampsia using atomic force microscopy indicate multiple changes at the microscopic level, which are the most likely cause of pregnancy complications. When studying erythrocytes inside the vessels of chorionic villi, myometrium and intervillous spaces in all the studied groups, a decrease in the number of discocytes and an increase in deformed and prehemolytic forms were revealed.

REFERENCES

1. Pavlova, T., Prashchayeu, K, Pozdnyakova, N., Bashuk, V., Selivanova A., 2013. Erythrocytes as target cells of diabetes types 1 and 2. *Virchows Archiv. The European Journal of Pathology. 25th European Congress of Pathology. European Society of Pathology*:157-158.
2. Pavlova T., Petrukhin, V., Selivanova, A., Goncharov, I., Kolesnicov, D., 2014. Issues in the study utero-placental blood flow in severe gestosis. *Virchows Archiv, 465 (Suppl 1)*:1-352.
3. Pavlova, T, Petruhin, V., Syrtseva, I., Selivanova, A., Markovskaya, V., Kolesnikov, D., Goncharov, I, Nesterov, A., 2015. Morphofunctional aspects of blood at preeclampsia. *Virchows Archiv, 467(Suppl 1)*:1-143.
4. Pavlova, T., Selivanova, A., Petrukhin, V., 2016. The usage of atomic power microscopy in nano-histological studies (at the example of preeclampsia). *Virchows Archiv.469 (Suppl 1)*:100. <https://doi.org/10.23888/PAVLOVJ201716-13>
5. V. Pavlova, T.V., Petruhin, B.A., Syrtseva, I.S., Selivanova, A.V., Markovskaya, V.A., 2017. Modern approaches to the study of erythrocytes of preeclampsia in the mother-placenta-fetus. *Journal of Pharmacy Research, 11(12)*:1575-1578.
6. Yarkov, S.P., Shilenko, I.V., Valiev, H.Kh., Karnet, Yu.N., Snegireva, N.S., Yanovsky, Yu.G., 2008. The study of the surface structure of immunochromatographic membranes by atomic force microscopy. *Almanac of clinical medicine, 17-2*: 377-380.
7. *Obstetrics / Edited by G.M. Savelyeva. - M.: Medicine, 2017.– 816 p. (In Russian)*
8. Dreval, A.V., *Reproductive endocrinology / Dreval A.V. - M.: GEOTAR-Media, 2019.– 240 p. (In Russian)*