



Neuroprotective and cerebrovascular effects of endogenous N-Arachidonoyl-GABA and its putative Cox-2 metabolite – GABA conjugate with Prostaglandin E2

Narine R. Mirzoyan¹, Nelly G. Khostikyan^{2†}, Vahe S. Meliksetyan^{1†}, Arpine A. Hakobyan¹, Tamara S. Gan'shina³, Melanya G. Baghdasaryan¹, Anna M. Arakelyan¹, Anna V. Gnezdilova³, Elena V. Kurza³, Natalia M. Gretskaya⁴, Vladimir V. Bezuglov⁴, Lusine Danielyan⁵, Ruben S. Mirzoyan³

1 *Clinical Pharmacology Department, Yerevan State Medical University after M. Heratsi, Yerevan, Armenia*

2 *Department of Pathological Anatomy and Clinical Morphology, Yerevan State Medical University after M. Heratsi, Yerevan, Armenia*

3 *V. V. Zakusov Research Institute of Pharmacology, Moscow, Russia*

4 *Shemyakin-Ovchinnikov Institute of Bioorganic Chemistry of Russian Academy of Sciences, Moscow, Russia*

5 *Department of Clinical Pharmacology, University Hospital of Tuebingen, Tuebingen, Germany*

Corresponding author: Narine R. Mirzoyan (nanamirzoyan@gmail.com)

Academic editor: M. Korokin ♦ Received 2 July 2021 ♦ Accepted 8 September 2021 ♦ Published 21 September 2021

Citation: Mirzoyan NR, Khostikyan NG, Meliksetyan VS, Hakobyan AA, Gan'shina TS, Baghdasaryan MG, Arakelyan AM, Gnezdilova AV, Kurza EV, Gretskaya NM, Bezuglov VV, Danielyan L, Mirzoyan RS (2021) Neuroprotective and cerebrovascular effects of endogenous N-Arachidonoyl-GABA and its putative Cox-2 metabolite – GABA conjugate with Prostaglandin E2. *Research Results in Pharmacology* 7(3): 49–61. <https://doi.org/10.3897/rrpharmacology.7.70974>

Abstract

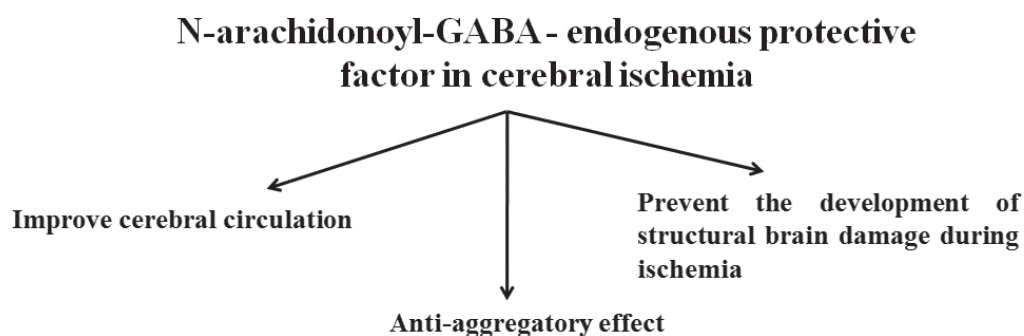
Introduction: The aim of the study was to compare the neuroprotective and cerebrovascular effects of bioactive, endogenous lipid – N-arachidonoyl-GABA (AA-GABA) and GABA conjugate with prostaglandin E2 (PGE2-GABA) by evaluation of a morphological state of rat brain tissue and lipofuscin levels under the condition of permanent focal brain ischemia, as well as cerebral circulation under the condition of global transient ischemia.

Materials and methods: The study has been implemented using the models of the left middle cerebral artery occlusion (MCAO) and global transient ischemia of the brain. A morphological examination of the brain tissue, a registration of local blood flow by laser flowmeter, and quantitative measurement of lipofuscin by fluorescence spectroscopy were used.

Results and discussion: AA-GABA and the putative COX-2 metabolite PGE2-GABA showed significant neuroprotective and cerebrovascular effects in rat models of global and focal cerebral ischemia. In the MCAO model, AA-GABA and PGE2-GABA at a dose of 2 mg/kg/day administered i.p. for 6 or 12 days led to: 1) significant restoration of neurons and glial cells with intracellular regeneration of cytoplasmic and nuclear structures, 2) decrease in brain tissue edema; 3) attenuated thrombosis and stasis, and 4) absence of large necrotic foci in rat brain tissue. AA-GABA and PGE2-GABA at the same dose prevented excessive accumulation of lipofuscin in both brain hemispheres in rats with MCAO. All the studied compounds increase cerebral blood circulation in rats subjected to global transient ischemia. However, the cerebrovascular effect of PGE2-GABA was superior to the activity of AA-GABA and all other tested compounds. AA-GABA and PGE2-GABA, unlike PGE2 and nimodipine, increase the cerebral blood flow in rats with global transient brain ischemia and have no influence on the intact animals. Apparently, the GABAergic vascular system of the brain is involved in the mechanisms of the neuroprotective action of AA-GABA and PGE2-GABA.

Conclusion: For the first time, we demonstrated the ability of **AA-GABA** and its putative metabolite COX-2 PGE2-GABA to improve cerebral circulation, attenuate structural damage and lipofuscin accumulation during cerebral ischemia. The natural origin of **AA-GABA**, which possesses neuroprotective and cerebrovascular activity, as well as anti-aggregatory activity, allows considering **AA-GABA** as one of the endogenous protective factors in ischemic brain lesions.

Graphical abstract:



Keywords

PGE2-GABA, **AA-GABA**, nimodipine, ethylmethylhydroxypyridine succinate (mexidol), focal permanent ischemia, global transient ischemia, brain tissue, lipofuscin, cerebral blood flow, bicuculline, GABA^A-receptors.

Introduction

Cerebrovascular diseases are leading among the main causes of mortality and disability of the population worldwide (Virani et al. 2021). The last decade was marked by the emergence of numerous data that proved the high efficiency of methods of restoring the blood supply to the ischemic brain (Park 2017; Shafie and Yu 2021), and this led to a radical revision of the concept of ischemic brain lesions therapy. Reperfusion therapy has spread, and the term reperfusion, which previously had a negative meaning and was associated with the release and damaging effects of free radicals (nitric oxide and oxygen) on brain tissue, has gained a positive meaning. Therefore, in the treatment of patients with cerebrovascular diseases of ischemic nature, the restoration of impaired blood supply to the brain, including drug-induced one, comes to the fore.

It should be noted that under conditions of cerebral ischemia, the GABA system plays an important role in eliminating the imbalance between the excitatory and inhibitory systems in the central nervous system. Besides its major contribution to inhibitory neurotransmission, the GABA system plays an important role also in regulation of cerebral vascular tone. GABA lowers the tone of cerebral vessels (Mirzoian and Akopian 1967), which contain GABA synthesizing enzyme (glutamate decarboxylase) as well as metabolizing enzyme (GABA transaminase) (Mirzoian et al. 1970; Mirzoian et al. 1974). Vascular glutamate decarboxylase appear to differ from that of neuronal tissue (Hamel et al. 1982), suggesting existence of a no-neural form of the enzyme. GABA^A receptors were identified in brain vessels of cattle (Krause et al. 1980), as well as in rat cerebral vessels (Napoleone et al. 1987).

GABAergic interneurons, which are an important component of the “neurovascular unit,” innervate both local micro vessels and neurons of the cerebral cortex and provide a blood supply corresponding to the functional state of neurons (Hamel et al. 2006). In conditions of ischemic brain damage, the GABA system exhibits neuroprotective activity (Schwartz-Bloom and Sah 2001; Li et al. 2020). Previous studies showed that compounds with GABAergic mechanism of action selectively improve the cerebral blood flow in conditions of ischemic damage of the brain (Mirzoyan et al. 2014, 2017; Kim et al. 2019).

Platelet aggregation and vascular tone regulation are among many different physiological effects known for prostaglandins (Bos et al. 2004). By regulating the vascular tone, they have a pronounced effect on the blood supply to various organs. **Prostaglandin E2** signaling is fulfilled via four different G-protein coupled membrane receptors EP1–EP4, mediating different and sometimes opposing responses. Previous studies showed that activation of PGE2 receptors EP1 and EP3 significantly exacerbate stroke injury in the model of focal cerebral ischemia (Shimamura et al. 2013). In opposite to EP1 and EP3 mediated effects, activation of EP2 and EP4 receptors leads to neuroprotection in stroke (Akram et al. 2013).

N-arachidonoyl gamma-aminobutyric acid (AA-GABA) is a member of endogenous lipid amides family, N-arachidonoyl amino acids (Bradshaw and Walker 2005). These compounds were found in mouse brain by quantitative LC-MS/MS analysis. The concentration of **AA-GABA** in the whole mouse brain was 5.3 ± 0.8 pmol/g like other arachidonoyl amino acids – **arachidonoyl glycine (AA-Gly)**, 13.1 ± 2.1 pmol/g, **arachidonoyl serine (AA-Ser)**, 3.1 ± 0.5 pmol/g, or **arachidonoyl alanine** (9.7 ± 1.9 pmol/g)

(Han et al. 2013). Recently, based on the ability of amides of **arachidonic acid** with **glycine**, serine and **GABA** to induce mesenteric relaxation, Parmar and Ho hypothesized that N-arachidonoyl amino acids represent a new group of vasomodulators. They demonstrated that the vasorelaxant activity within this group changed in descending order of potency, **AA-GABA** > **AA-Gly** > **AA-Ser**. Effects of all three endogenous conjugates of **arachidonic acid** and amino acids were sensitive to **L-NAME** (L-NG-Nitro arginine methyl ester, inhibitor of nitric oxide synthase) and **iberiotoxin** (selective inhibitor of large conductance Ca²⁺-activated K⁺ channel – BKCa), suggesting a role for nitric oxide and BKCa in a mechanism of relaxation (Parmar and Ho 2010). Other researchers investigated effects of **AA-GABA**, including its analgetic action via inhibition of T-types Cav3 calcium channels (Barbara et al. 2009), Ca²⁺ mobilization in TRPV1 HEK cells and in BV-2 microglia (Raboune et al. 2014), and anti-aggregatory activity (Vasilieva et al. 2010). The biological effects of PGE2-GABA are completely unknown, although the existence of this possible **AA-GABA** metabolite of cyclooxygenase-2 has been postulated (Marnett et al. 2008).

Lysosomes of some cell types, particularly neuronal cells, are known to accumulate net-products of damage, the excess of which can cause irreversible damage to those cells. One of such products is lipofuscin, the so-called “aging pigment”, which contains peroxidized proteins and lipids, the excess amounts of which has been shown to cause inability of cells to eliminate products of oxidative damage (Jung et al. 2007). It has been experimentally proven that the mechanisms of formation and composition of lysosomal pigments formed during aging and during ischemia are very similar (Terman and Brunk 2004; Jung et al. 2007). Notably, focal permanent ischemia caused by MCAO leads to an increase in the concentration of lipofuscin in both hemispheres of the rat brain (Balasanyan et al. 2013), and the use of **ethylmethylhydroxypyridine succinate** (**mexidol**) prevents excessive accumulation of lipofuscin in brain tissues after MCAO (Mirzoyan et al. 2015a).

Previously, we studied the effect of **AA-GABA** on the morphological state of rat brain tissue in the MCAO model, as well as on platelet aggregation and cerebral circulation. We have previously shown that 6- and 12-day course administration of **AA-GABA** at a dose of 2 mg/kg (i.p.) to rats under the conditions of this model led to the processes of significant restoration of brain tissue. The tissue morphology in the group of animals that received **AA-GABA** for 12 days was almost identical to the state of the intact tissue (Mirzoyan et al. 2015b). Moreover, **AA-GABA** significantly inhibited arachidonic acid-induced platelet aggregation. Consequently, **arachidonic acid** conjugated with **GABA** is converted from a pro-aggregant into an anti-platelet agent (Vasilieva et al. 2010). Also the selective cerebrovascular activity of **AA-GABA** was revealed. **AA-GABA** increased the blood supply to the brain only under the condition of global transient cerebral ischemia (Gnezdilova et al. 2011).

In compliance with the above mentioned, the aim of the current comparative study was the investigation of the neuroprotective and cerebrovascular effects of PGE2-GABA and **AA-GABA** in condition of focal permanent brain ischemia caused by MCAO, with evaluation of morphological state of brain tissue and lipofuscin levels. The study aimed also at the comparative investigation of the effects of PGE2-GABA, PGE2, **AA-GABA**, **nimodipine**, and **ethylmethylhydroxypyridine succinate** on the cerebral blood flow of the intact rats and the rats exposed to global transient brain ischemia. Further, we analyzed the mechanism of neuroprotective and cerebrovascular effects of the studied compounds.

Materials and methods

Substances

The compounds under study were synthesized in the Laboratory of Oxylipins of Shemyakin-Ovchinnikov Institute of Bioorganic Chemistry of the Russian Academy of Sciences (Russia), according to the published procedures (Bezuglov et al. 2006, 2013, 2015). **Prostaglandin E2** (CAS 363-24-6) was obtained from Merck (Darmstadt, Germany), **nimodipine** – from Bayer AG (Germany), and **ethylmethylhydroxypyridine succinate** (**mexidol**) from FSBI V.V. Zakusov Institute of Pharmacology (Russia).

Animals

The study was performed on 112 albino male rats weighing 150–250 g, anesthetized with **chloral hydrate** (400 mg/kg) or **urethane** (1.2 g/kg), i/p. The experiments were carried out in compliance with the ethical rules of animal welfare according to the European Communities Council Directive (86/609/EEC).

Design

A model of focal cerebral ischemia was performed by the left-sided middle cerebral artery occlusion (MCAO), according to Tamura et al. (Tamura et al. 1981), in the modification of Topchian et al. (Topchian et al. 1996). The surgery was performed under **chloral hydrate** anesthesia (400 mg/kg, i/p). The investigated compound was administered at a dose 2 mg/kg i.p. 30 minutes after the occlusion and on the following 6 and 12 days, respectively. The control group received 0.9% NaCl solution i.p.

Global transient ischemia in rats was achieved by 10-minute occlusion of both common carotid arteries with a simultaneous decrease in the arterial pressure down to 40–50 mm Hg, using bloodletting and further reperfusion. The investigated compounds were administered i.v. 40–45 minutes after global transient brain ischemia and stabilization of the hemodynamic parameters.

The morphological assessment of brain tissue and the quantitative measurement of lipofuscin in the brain tissue

were performed on the 6th and 12th days after MCAO. These intervals were chosen based on the recent data, according to which the most profound structural changes in the brain after MCAO in rats are seen on 6th and 12th days (Mirzoyan et al. 1998).

To conduct a morphological examination, the brain was extracted and fixed in 10% neutral solution of formaldehyde. Then sagittal incision was made, including in tissue supplied by the middle cerebral artery. Thereafter, the tissue was fixed in a paraffin block and cut with a microtome. Serial tissue sections were stained with hematoxylin/eosin.

For the quantitative measurement of lipofuscin, brain tissue (0.2 g) from each hemisphere was homogenized for 1 minute and was centrifuged at 1300 rpm in a solution of chloroform-methanol (2:1 v:v) at a ratio of 20:1 (v:w). Subsequently, after extraction of the water-soluble components with an equal volume of distilled water, centrifugation on the T30 apparatus at 3000 rpm for 1–2 minutes, and separation of the chloroform layer, methanol was added (0.1 ml per each ml of the final solution) to restore transparency. The resulting solution was exposed to intensive ultraviolet light for 3 minutes to eliminate fat-soluble components that could interfere with measurement (retinol, in particular) (Fletcher et al. 1973). The fluorescence intensity (FI) of chloroform extracts obtained from homogenized brain tissue was measured on a fluorescent spectrophotometer (MF-2A, Hitachi, Ltd. Tokyo, Japan) at an excitation wavelength of 365 nm and emission wavelength of 470 nm. Immediately before the measurement, the fluorometer was calibrated with a solution of quinine sulfate 0.1 µg/ml (CP) in 0.1 N sulfuric acid solution (FI = 60–90) (Csallany and Ayaz 1976).

Cerebral blood circulation was recorded by the laser Doppler flowmetry. Changes of arterial pressure were registered simultaneously through a polyethylene catheter, preliminary inserted into the femoral artery. The recording of the characteristics of blood flow, arterial pressure, and vascular resistance was conducted on a BIOPAC polygraph (USA), connected to a computer. The investigated compounds were administered through a polyethylene catheter into the femoral vein of the animals.

Statistical analyses

The statistical analysis of data was carried out using Statistica 8.0 software (Statistica Inc., USA), Microsoft Office Excel 2010, as well as GraphPad Prism 8.00 for Windows (GraphPad Software, Inc) and a one-way ANOVA variance analysis, with the Student's T-test. The normal distribution was defined by Shapiro-Wilk test. Generally, normal distribution was lacking; thus for a further analysis, nonparametrical method of Wilcoxon signed-rank test was used for linked samples, whereas for independent samples, the Mann-Whitney test was used. The results were considered statistically significant with $p < 0.05$. The data are shown as mean±SD (or SEM).

Results

The influence of PGE2-GABA on morphological state of brain tissue after the occlusion of middle cerebral artery

In order to study the neuroprotective effect of PGE2-GABA, its influence was observed on morphological damage of brain tissue provoked by MCAO.

The morphological examination of specimens of the first control group (6 days after MCAO without treatment) revealed a pronounced perivascular and pericellular edema of the brain tissue in the basin of the left middle cerebral artery. In the edematous brain tissue, cells with vacuolar dystrophy of the cytoplasm and the nucleus of neurons, areas of karyorexis, karyopiknosis and karyolysis of nerve and glial cells were detected. Stasis of capillaries and arterioles, as well as microthrombosis was observed along with empty microcirculatory vessels. These arterioles were surrounded by emptied neural and glial cells. All the layers of cortical cells were permeated by zones of necrobiosis with wash-out, lysis of nuclei of neurons, and large glial cells. Also extensive foci of necrosis of the brain tissue in the basin of the left middle cerebral artery, as well as microcysts in necrotic brain tissue were detected (Fig. 1a, b).

Anucleate, necrotic shadow cells, as well as areas of dystrophic neurosecretory cells of paraventricular and supraoptic (PV and SO) nuclei were detected. The borders of all the cortical layers appeared faded. Several hypertrophied neurons with hyperchromic nuclei were observed between or near the profound ischemic foci. Proliferation zones of oligodendrocytes and astrocytes were found throughout the brain tissue. Multiple punctuate and linear hemorrhages, edema, as well as stasis of vessels of pia and dura mater were detected. There were small-pointed and more extensive hemorrhages with siderophages in the intercellular space.

We further compared the above changes with those from the next group of control animals decapitated on day 12 after MCAO. In most cases, processes of beginning regeneration, such as intracellular organelle hyperplasia, were observed on the 12th day after MCAO. Single or small clusters of hypertrophied neurons were found in areas of the neural tissue with prominent anastomosis of small collateral arterioles, or in the area of preserved vessels with plethora of arterioles. In the basin of the left middle cerebral artery, there were linear hemorrhages, edema of the pia and dura mater, pronounced destructive-ischemic changes, as well as multiple vessels with stasis (Fig. 1c, d).

The obtained results correspond to the published data of previous studies that showed bilateral disturbances of brain blood flow, hypoxic damage to the cortical neuron in the same periods after MCAO (Mirzoyan et al. 1998; Mirzoyan et al. 2015).

We further studied the influence of PGE2-GABA (2 mg/kg, i/p) on the morphological state of brain tissue of rats with MCAO after 6 days of treatment.

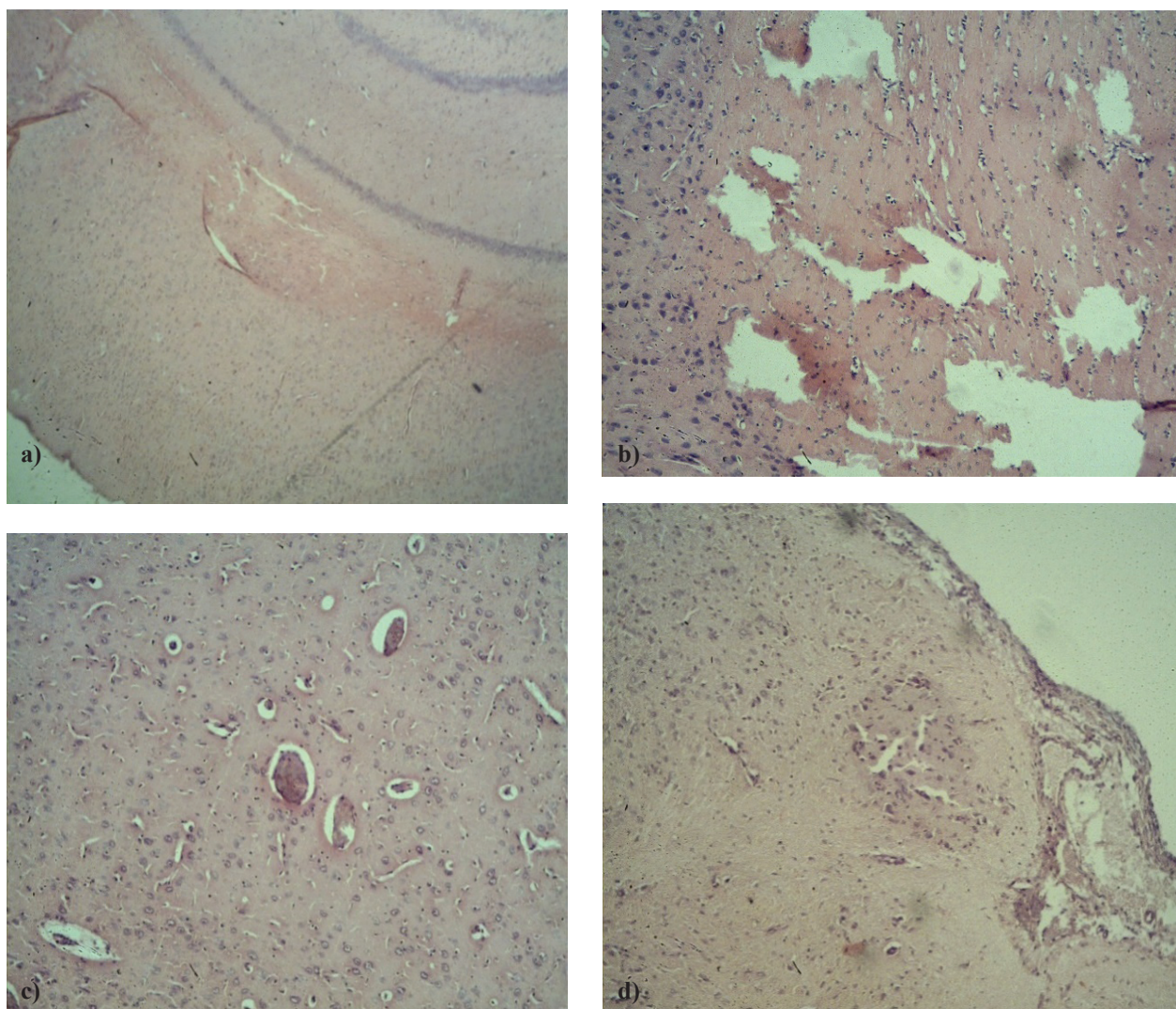


Figure 1. Morphological picture of brain tissue of drug-untreated rats after MCAO. 6th day: a) Large necrotic zones of brain tissue in basin of the left middle cerebral artery. Zones of homogeneous structureless substance (staining by hematoxylin/eosin $\times 100$). b) Zones of microcysts in necrotic brain tissue. Preserved layers of nerve cells (staining by hematoxylin/eosin $\times 100$). **12th day:** c) Stasis of microvessels, thrombus obliterans, an expressed perivascular and pericellular edema, foci of necrosis and necrobiosis in brain tissue (staining by hematoxylin/eosin $\times 100$). d) Edema, hemorrhages in pia mater. Among the necrotic foci, several zones of groups of preserved neurons are detected (staining by hematoxylin/eosin $\times 100$).

Histological evaluation revealed slight plethora of the vessels of the pia mater, as well as diminished edema of the pia and dura mater. Attenuated perivascular and pericellular edema was also detected in the brain tissue with foci of plethora of arteries and arterioles. In the basin of the left middle cerebral artery, there were detected single groups of neural cells with wrinkled nuclei and vacuolar dystrophy of the cytoplasm, as well as foci with neurons with blurred contours and boundaries. Appearance of these shadow cells can be accounted for by the state of necrobiosis. Along with such foci, small areas were observed with accumulation of structureless eosinophilic masses at the site of necrotized nerve cells. The pyramidal cells and axons in the III pyramidal zone (layer) appeared to be preserved. Among the intact cells, there could be observed hypertrophied neurons with pronounced hyperchromic nuclei (Fig. 2a). Large and small glial cells in the III

and IV layers of the cerebral cortex appeared to be without visible changes. In some zones, proliferation of glial cells at the background of edema of the reticular neuropile was observed. Ependymal cells of the brain ventricles remained preserved and without visible morphological changes. In some fields, proliferation of ependymal cells and plethora of arterioles in the ependymal membrane of the III brain ventricle were observed (Fig. 2b). The cells of the PV and SO nuclei of the hypothalamus remained intact with neurosecretory granules detected in their cytoplasm. Some cells of the PV and SO nuclei appeared hypertrophic with hyperchromic nuclei. With an exception of few brain sections showing edema of the hard and soft meninges with vascular plethora, no visible histological changes were revealed from the meninges. Mild perivascular and pericellular edema with plethora of capillaries was observed in the brain tissue of this MCAO group. The location

of the neurons of the gray matter layers was predominantly unchanged. In the first and second granular zones, small foci of ischemia and necrobiosis of the cells, as well as some dystrophic neurons were detectable. We observed multiple anastomoses between the axons and dendrites of the pyramidal cells of the gray matter and the continuity of nerve processes, including axons, was preserved.

After 12-day treatment by PGE₂-GABA, the observable morphological changes in the brain tissue were more visible compared to those after the 6-day administration of the compound. In most sections, several brain tissue zones resembled the normal structure. In five animals, no MCAO-induced changes, such as necrotic fields, were found. Pyramidal cells are well contoured with their axons throughout; insignificant pericellular edema, as well as neuropile without changes, was observed

(Fig. 2c). In the observed necrotic fields due to ischemia, pronounced productive proliferative processes in the glial tissue of the brain were visible. The neurons of III, IV, and V zones of the brain tissue remained preserved. The neurosecretory cells of the PV and SO nuclei of the hypothalamus appeared to have functionally active morphology, with multiple neurosecretory granules in their cytoplasm (Fig. 2d). Ependymal cells of the ventricles of the brain remained morphologically unchanged. In some foci of the III ventricle, the proliferation of the ependymal cells and the cells of vascular plexus was observed. No specific visible abnormalities were found in the morphology of the dura and pia mater; besides occasionally plethora of vessels and single extravasates could be observed.

The morphological evaluation of the right intact hemisphere of the brain revealed the presence of compensatory

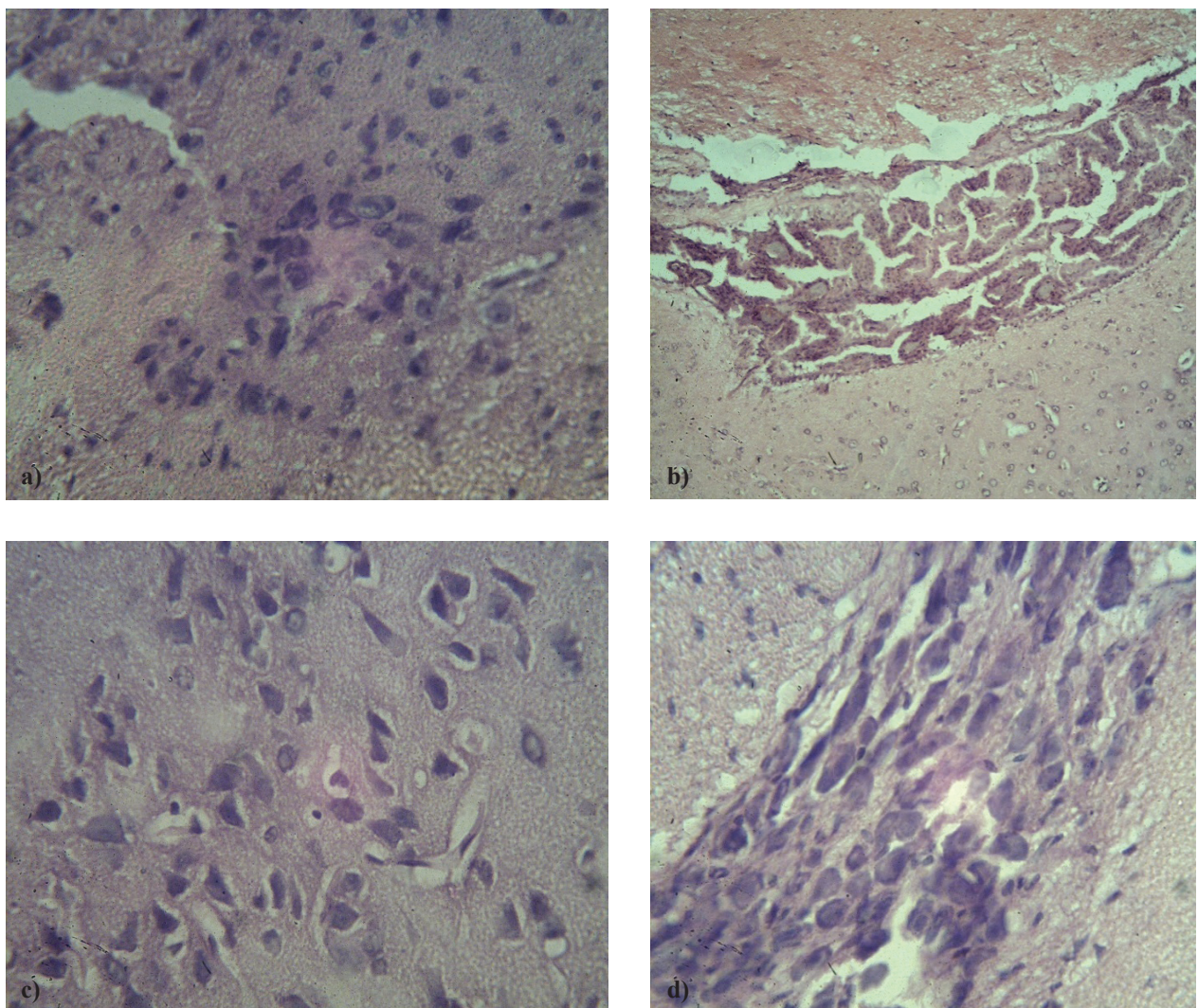


Figure 2. Morphological picture of brain tissue of rats after MCAO treated with PGE₂-GABA. 6-days treatment: a) Groups of hypertrophied hyperchromic neurons among the foci of micronecrosis in the brain tissue are detected, insignificant brain tissue edema, neuropile preserved (staining hematoxylin/eosin $\times 400$). b) Significant proliferation of the vessels of the III ventricle with proliferation of ependymal cells (staining hematoxylin/eosin $\times 200$). **12-days treatment:** c) Hypertrophied pyramidal cells with hypertrophied nuclei and preserved processes, insignificant pericellular edema, neuropil without visible histological changes (staining hematoxylin/eosin $\times 400$). d) Significant hypertrophy of neurosecretory cells of PV nucleus of hypothalamus with the neurosecretory granules in cytoplasm (staining hematoxylin/eosin $\times 400$).

regenerative processes. In the background of slight brain tissue edema, normal or hypertrophied neurons were detected. Intact structure and morphology of all the areas of the cerebral cortex, the preserved neurosecretory SO and PV nuclei of the hypothalamus, the absence of large necrotic areas, and a slight plethora of arterial vessels were observed in the group of MCAO rats with 12-day treatment by PGE2-GABA.

Taken together, the morphological studies of rat brain with MCAO after administration of PGE2-GABA revealed a large number of hyperchromic, functionally active pyramidal nerve cells with preserved processes, very small foci of ischemia with proliferation of glial cells, restoration of microvessels in the form of plethora of capillaries and arterioles, functionally active neurosecretory cells and intracellular regeneration of neurons in general and neurosecretory cells in particular. Compared to the brain tissue of the control animals (after MCAO without treatment), foci of ischemia and necrosis, dystrophy and necrobiosis were much less pronounced, both in terms of localization and depth of the lesions. The use of the studied compound led to significant restoration of neurons and glial cells with intracellular regeneration of cytoplasmic and nuclear structures, to decreased brain tissue edema, thrombosis and stasis, as well as to the absence of large necrotic foci. It should be noted that the reparative effect of PGE2-GABA was already detectable in the animals treated with the compounds for 6 days, and was enhanced by a prolonged treatment for 12 days (compared to a 6-day use).

The influence of PGE2-GABA on lipofuscin levels

Another objective of this study was the investigation of lipofuscin levels in brain tissues after focal permanent ischemia caused by MCAO in both intact and damaged

hemispheres of the brain. In the intact animals, the concentration of lipofuscin in the left and right hemispheres appears to be nearly identical – 2.52 ± 0.70 FI vs. 2.6 ± 0.58 FI, respectively (Fig. 3).

The results of lipofuscin levels on the 6th day after MCAO revealed a statistically significant increase in both ipsilateral (7.01 ± 1.32 FI) and contralateral (6.62 ± 1.25 FI) hemispheres in comparison with the intact animals (Fig. 3). Similar significant changes in the left and right hemispheres were observed on the 12th day after occlusion (left hemisphere – 5.70 ± 1.34 FI; right hemisphere – 5.61 ± 1.14 FI) (Fig. 3). Moreover, in the left hemisphere, both on the 6th and the 12th days of ischemia, there was a more significant increase in lipofuscin levels in comparison with those in the right hemisphere. Some observable decrease in lipofuscin levels, which occurs without any treatment on the 12th day after occlusion, may be a result of intrinsic regenerative processes in the brain tissue.

After 6 days of treatment with the PGE2-GABA, a statistically significant decrease in the amount of lipofuscin in both hemispheres (left hemisphere – 4.36 ± 1.24 FI; right hemisphere – 4.24 ± 1.23 FI) were found. As for the results of the 12-day treatment (left – 3.48 ± 0.97 FI; right – 3.28 ± 0.91 FI), the changes are obvious compared with control (Fig. 3).

The obtained data showed that PGE2-GABA prevents excessive accumulation of lipofuscin in tissues in condition of focal permanent ischemia. Intraperitoneal administration of the compound at a dose of 2 mg/kg over 6- as well as 12-days led to statistically significant prevention of lipofuscin accumulation in both hemispheres of rat brain with MCAO.

Based on the recent data on elevated lipofuscin levels in ischemic brain tissue, our results can be considered as additional evidence of neuroprotective effects of the studied compound.

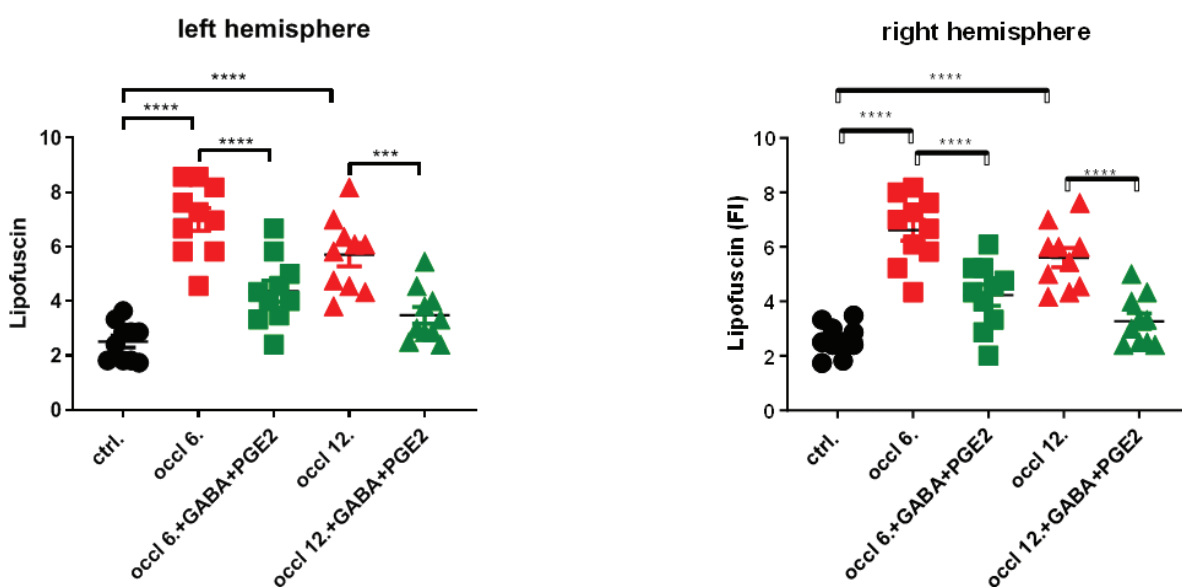


Figure 3. Changes of lipofuscin levels, shown as fluorescence intensity (FI), in the left and right hemispheres of rats' brain after PGE2-GABA treatment and MCAO.

Effect of PGE2-GABA on local blood flow of the cerebral cortex in intact rats and rats with global transient ischemia in comparison to PGE2, AA-GABA, nimodipine, and ethylmethylhydroxypyridine succinate (mexidol)

The evaluation of PGE2-GABA (0.1 mg/kg i/v) influence on the cerebral circulation of the intact rats revealed no changes in either local cerebral blood flow or blood pressure. Under the condition of global transient brain ischemia, PGE2-GABA immediately after its administration increased the local cerebral blood flow by an average of 16% ($p \leq 0.05$), which was further increased to a maximum of 110.6% ($p \leq 0.05$) 70 minutes after administration. Thereafter a gradual decrease in blood flow reaching the initial level was detected 120 minutes after administration of PGE2-GABA (Figs 4 and 5). The cerebrovascular effect of PGE2-GABA is due to its obvious effect on the tone of the brain vessels, since the level of blood pressure in the majority of the experiments decreases, whereas in the rest – it does not undergo any changes.

PGE2 (0.2 mg/kg) increased the local cerebral blood flow in the brain cortex of the ischemic animals as well as of the intact rats (though to a lesser extent). PGE2 increased arterial blood pressure by 16% on average.

Further, we compared the structural analogue of prostaglandin E2 with drugs that are widely used as

cerebrovascular anti-ischemic drugs, namely - nimodipine and ethylmethylhydroxypyridine succinate (mexidol).

A study of the effect of prostaglandin E2 on cerebral blood flow under the condition of global transient ischemia showed that the drug, when administered intravenously at a dose of 0.2 mg/kg, caused an increase in local cerebral blood flow immediately after its administration, reaching a decrease by 46.6% after 60 minutes (Fig. 5). Then, blood flow decreased slightly, but remained elevated until the end of the experiment. The level of blood pressure under the influence of PGE2 initially increased slightly, and then decreased and at the end of the experiment amounted to 13.6% of the baseline (control in Fig. 5) value.

After global transient ischemia, AA-GABA at a dose of 2 mg/kg increases local cerebral blood flow immediately after its administration by an average of 21.6% and reaches its maximum value (44.1%) 80 minutes after administration (Fig. 4). Then the blood flow gradually decreases, but remains above the control level until the end of the experiments. These results showing a dual effect of AA-GABA on the blood pressure are in line with the previous report, showing that after global transient ischemia, AA-GABA decreased blood pressure by an average of 15% in half of the experiments, while in the other half it increased by an average of 20% (Gnezdilova et al. 2011).

In conditions of ischemic brain damage, nimodipine at a dose of 0.03 mg/kg also causes an increase in local

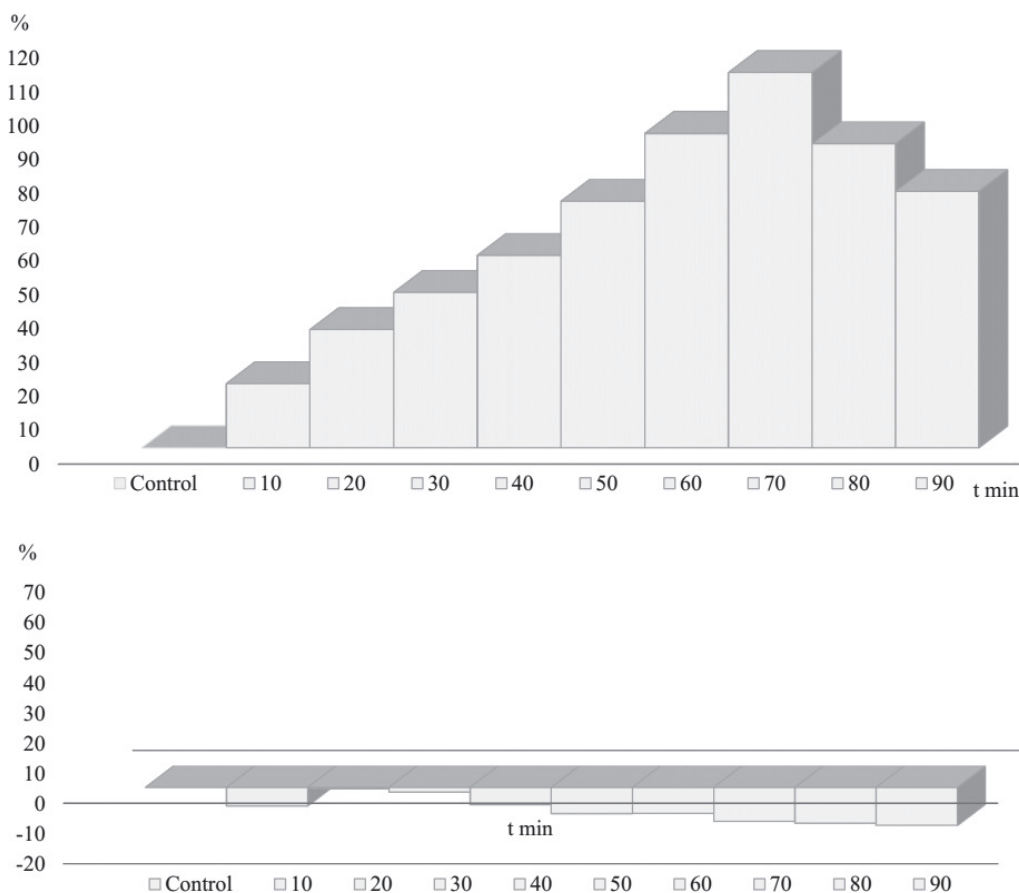


Figure 4. The influence of PGE2-GABA(0.1 mg/kg, i/v) on local blood flow (A, LBF, %) and arterial blood pressure (B, BP, %) in rats after global transient ischemia.

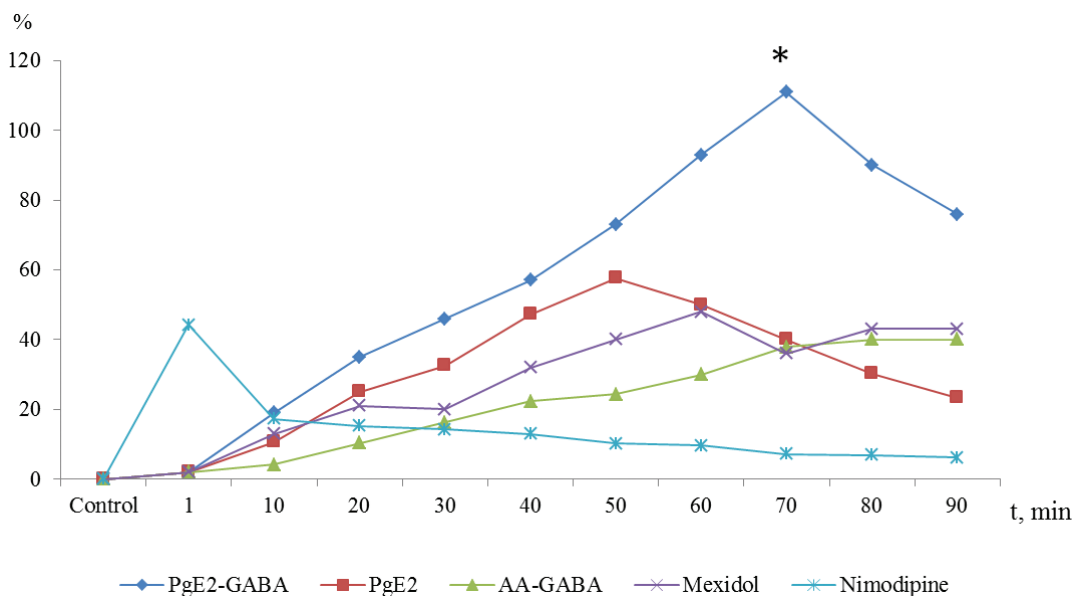


Figure 5. The influence of PGE2-GABA (0.1 mg/kg i/v), PGE2 (0.2 mg/kg, i/v), AA-GABA (2 mg/kg, i/v), ethylmethylhydroxypyridine succinate (mexidol, 200 mg/kg, i/v) and nimodipine (0.03 mg/kg, i/v) on local blood flow in brain cortex of rats after global transient ischemia (%) (* – $p \leq 0.05$ PGE2-GABA compared with other drugs).

cerebral blood flow immediately after its administration by an average of 44.3%, while a concomitant decrease in blood pressure by an average of 39.6% was detected. After 10 minutes, the effect of nimodipine is weakened, reaching an average 17.3% and remaining at this level until the end of the experiment (Fig. 5).

Ethylmethylhydroxypyridine succinate (mexidol) at a dose of 200 mg/kg in rats after global transient ischemia causes a gradual increase in local blood flow in the parietal zone of the cerebral cortex, which reaches 43% by the 50th minute (Fig. 5). In those experiments, the level of blood pressure slightly decreased after 10 minutes, but remained at the same level from the 20th minute until the end of the experiment.

Our results show that PGE2-GABA causes the most pronounced effect on the blood supply to the brain of rats exposed to global transient ischemia, compared with AA-GABA, nimodipine and ethylmethylhydroxypyridine succinate (Fig. 5). The difference between the PGE2-GABA and the other drugs is statistically significant ($p \leq 0.05$).

PGE2 also demonstrates cerebrovascular anti-ischemic effects; however, it is significantly inferior to those of PGE2-GABA (Fig. 5). Thus, it can be assumed that the presence of GABA in the structure of the conjugate of GABA with prostaglandin E2 enhances the cerebrovascular activity of prostaglandin E2 under the conditions of brain ischemia.

The investigation of neurochemical mechanisms of action of AA-GABA, PGE2-GABA, and PGE2

Considering the important role of GABAergic mechanisms in the regulation of cerebral blood circulation, the effect of pharmacological agents on the local cerebral blood flow of rats subjected to global transient ischemia and administration of a specific GABA^A-receptors antagonist

– bicuculline – was studied. Bicuculline was administered at a dose of 0.5 mg/kg after ischemic damage of the brain, but prior to administration of AA-GABA, PGE2-GABA or PGE2, which were administered 30 minutes after bicuculline treatment.

The cerebrovascular effect of AA-GABA was leveled out by the GABA^A-receptor blockade with bicucullin which was reflected by a lack of AA-GABA effects in most experiments (6 out of 10), while the rest revealed a slight increase in blood flow (6–10%, control – 44.1%), and a decrease in blood pressure by an average of 15%.

The use of PGE2-GABA with bicuculline insignificantly increased or did not change the local cerebral blood flow.

PGE2 demonstrated a vasodilator effect with and without the influence of the antagonist of GABA^A-receptors – bicuculline – in global transient ischemia. Thus, the effect of PGE2 is apparently due to activation of prostaglandin receptors in cerebral vessels.

Our results indicate the involvement of GABA-ergic system in cerebrovascular effects of AA-GABA and PGE2-GABA in brain ischemia.

Discussion

The obtained data indicate the protective effect of PGE2-GABA on brain tissue during MCAO-caused focal permanent ischemia. Its use leads to significant restoration of blood circulation and morphological recovery of brain tissue in the basin of the left middle cerebral artery. The effectiveness of the compound is enhanced by its longer use (12 days) compared to 6-day administration. In line with our previous results (Mirzoyan et al. 2015b),

AA-GABA has a similar effect to that of PGE2-GABA during ischemic brain injury.

The neuroprotective activity of PGE2-GABA is indicated by the statistically significant prevention of accumulation of lipofuscin as a supposed marker of ischemia in both hemispheres of rat brain in MCAO after 6-day, as well as 12-day administration of the compound.

PGE2-GABA causes a more significant increase in the cerebral blood flow in the model of global transient brain ischemia (to 110.6%, $p \leq 0.05$), compared to **AA-GABA** (to 44.1%) and anti-ischemic drug – **nimodipine** (to 44.3%). This effect of PGE2-GABA and **AA-GABA** is blocked by **bicuculline**, acting via GABA^A-receptors of the brain vessels. **Bicuculline** has no impact on the cerebrovascular activity of **nimodipine**. The vasodilator effect of **nimodipine** could be seen at both intact and ischemic brains due to blocking only slow calcium channels.

The superior anti-ischemic cerebrovascular activity of PGE2-GABA in comparison to the other drugs investigated in this study could be explained by its double vasodilator effect mediated by two different receptor systems within the vascular wall of cerebral vessels: prostaglandin and GABA^A-receptors. In this context, a possible hint at prostaglandin receptor-mediated neuroprotection by the studied PGE2-GABA is provided by the previous reports demonstrating neuroprotective effects of EP4 receptor activation in a transient MCAO stroke model (Parmar and Ho 2010; DeMars et al. 2018).

The results of the present study are consistent with our previously shown neuroprotective and cerebrovascular effects of the compounds enhancing GABA-ergic neurotransmission (Mirzoyan et al. 2014; Mirzoyan et al. 2019). Considering the currently existing notion about disbalance between excitatory and inhibitory systems during ischemic damage of the brain, GABA agonists increase the activity of inhibitory processes mediated by GABA-receptors and restore the balance between these systems. In addition, GABA agonists lower the brain vascular tone, thus, improving blood supply of an ischemic zone. Our previous studies of rat brain in the conditions of global transient ischemia have shown increasing of the **glutamate** concentration in rat striatum, as well as changes in catalase, stress protein HSP70 and nerve growth

factor (NGF) concentrations in brain tissue (Silkina et al. 2006; Antipova et al. 2009; Baykova et al. 2011). It can be assumed that PGE2-GABA prevents these disturbances by multiple influencing the mechanisms regulating the cerebral blood supply.

We can propose that PGE2-GABA, a putative COX-2 metabolite of **AA-GABA**, can be formed under stress condition, such as ischemic brain injury. This notion is based on the data on increased levels of PGE2 and COX-2 during brain ischemia (Zhang et al. 2003). Thus, it can be assumed that increased synthesis of endogenous **AA-GABA** would lead to prolonged and/or augmented neuroprotective and cerebrovascular effects due to its consequent transformation to an active conjugate PGE2-GABA.

Conclusion

This study demonstrates for the first time that endogenous **AA-GABA** and its putative COX-2 metabolite PGE2-GABA exhibit significant neuroprotective and cerebrovascular effects in conditions of local and global cerebral ischemia. Taking into account the endogenous origin of N-arachidonoyl-GABA, and our results, showing its anti-aggregatory effect and ability to improve cerebral circulation, to restore brain tissue and to diminish lipofuscin accumulation during cerebral ischemia, **AA-GABA** and potentially its metabolite (PGE2-GABA) can be considered as endogenous protective factors in ischemic brain lesions.

Our results on the studied compound provide the basis for the development of new neuroprotective anti-ischemic drugs acting at GABA-ergic and PGE2 receptor systems in the brain.

Conflicts of Interests

The authors declare no conflict of interests.

Funding

This research received no external funding.

References

- Akram A, Gibson CL, Grub BD (2013) Neuroprotection mediated by the EP (4) receptor avoids the detrimental side effects of COX-2 inhibitors following ischaemic injury. *Neuropharmacology* 65: 165–172. <https://doi.org/10.1016/j.neuropharm.2012.09.010> [PubMed]
- Antipova TA, Logvinov IO, Kurdyumov IN, Mirzoyan NR, Gan'shina TS, Turilova AI, Mirzoyan RS, Seredenin SB (2009) Effect of afobazole on stress protein HSP70 content in brain tissue of rats with global transient ischemia. *Experimental and Clinical Pharmacology [Eksperimentalnaya i Klinicheskaya Farmakologiya]* 72(1): 29–32. [PubMed] [in Russian]
- Balasanyan MG, Afrikyan ShG, Grigoryan TS (2013) Quantitative changes in lipofuscin under conditions of ischemic brain disorders under the influence of noopept and citicoline. *PhysioMedi* 1: 7–12.
- Barbara G, Alloui A, Nargeot J, Lory P, Eschalier A, Bourinet E, Chemin J (2009) T-type calcium channel inhibition underlies the analgesic effects of the endogenous lipoamino acids. *Journal of Neuroscience* 29(42): 13106–13114. <https://doi.org/10.1523/JNEUROSCI.2919-09.2009> [PubMed] [PMC]
- Baykova VS, Kadnikov IA, Voronin MV, Ganshina TS, Gnezdilova AV, Gorbunov AA, Mirzoyan RS, Seredenin SB (2011) Effect of afobazole

- on the content of neurotransmitter amino acids in the striatum in global transient ischemia. *Bulletin of Experimental Biology and Medicine* 151(5): 593–596. <https://doi.org/10.1007/s10517-011-1390-0>
- Bezuglov VV, Bobrov MYu, Gretskeya NM, Serkov IV, Zinchenko GN, Akimov MG (2013) Neuroprotective prostamide and its analogs. RU 2474426, Database: CAPLUS.
 - Bezuglov VV, Gretskeya NM, Akimov MG, Zinchenko GN, Tukhovskaya EA, Murashe AN (2015) Prostaglandin derivatives with anti-inflammatory and analgesic activities. RU 2568603 Database: CAPLUS.
 - Bezuglov VV, Gretskeya NM, Blazhenova AV, Adrianova EL, Akimov AV, Bobrov MIu, Nazimov IV, Kisel' MI, Sharko OL, Novikov AV, Krasnov NV, Shevchenko VP, V'iunova TV, Miasoedova NF (2006) Arachidonoyl amino acids and arachidonoyl peptides: Synthesis and properties. *Russian Journal of Bioorganic Chemistry* 32(3): 231–239. <https://doi.org/10.1134/S1068162006030046>
 - Bos CL, Richel DJ, Ritsema T, Peppelenbosch MP, Versteeg HH (2004) Prostanoids and prostanoid receptors in signal transduction. *The International Journal of Biochemistry & Cell Biology* 36(7): 1187–1205. <https://doi.org/10.1016/j.biocel.2003.08.006>
 - Bradshaw HB, Walker JM (2005) Prostanoids and prostanoid receptors in signal transduction. *British Journal of Pharmacology* 144(4): 459–465. <https://doi.org/10.1038/sj.bjp.0706093>
 - Csallany AS, Ayaz KL (1976) Quantitative determination of organic solvent soluble lipofuscin pigments in tissues. *Lipids* 11(5): 412–417. <https://doi.org/10.1007/bf02532849> [PubMed]
 - DeMars KM, McCrea AO, Siwarski DM, Sanz BD, Yang C, Candelario-Jalil E (2018) Protective effects of L-902,688, a prostanoid EP4 receptor agonist, against acute blood-brain barrier damage in experimental ischemic stroke. *Frontiers in Neuroscience* 12: 89. <https://doi.org/10.3389/fnins.2018.00089> [PubMed] [PMC]
 - Fletcher BL, Dillard CJ, Tappel AL (1973) Measurement of fluorescent lipid peroxidation products in biological systems and tissues. *Analytical Biochemistry* 52(1): 1–9. [https://doi.org/10.1016/0003-2697\(73\)90327-8](https://doi.org/10.1016/0003-2697(73)90327-8) [PubMed] <https://www.sciencedirect.com/science/article/abs/pii/0003269773903278?via%3Dihub>
 - Gnezdilova AV, Gan'shina TS, Maslennikov DV, Bezuglov VV, Gretskeya NM, Mirzozian RS (2011) Cerebrovascular effects of GABA conjugate with arachidonic acid under conditions of separate and combined vascular pathology of brain and heart. *Experimental and Clinical Pharmacology [Eksperimentalnaya i Klinicheskaya Farmakologiya]* 74(8): 28–31. [PubMed] [in Russian]
 - Hamel E (2006) Perivascular nerves and the regulation of cerebrovascular tone. *Journal of Applied Physiology* 100(3): 1059–1064. <https://doi.org/10.1152/jappphysiol.00954.2005> [PubMed]
 - Hamel E, Krause DN, Roberts E (1982) Characterization of glutamic acid decarboxylase activity in cerebral blood vessels. *Journal of Neurochemistry* 39(3): 842–849. <https://doi.org/10.1111/j.1471-4159.1982.tb07969.x> [PubMed]
 - Han B, Wright R, Kirchoff AM, Chester JA, Cooper BR, Davison VJ, Barker E (2013) Quantitative LC-MS/MS analysis of arachidonoyl amino acids in mouse brain with treatment of FAAH inhibitor. *Analytical Biochemistry* 432(2): 74–81. <https://doi.org/10.1016/j.ab.2012.09.031> [PubMed] [PMC]
 - Jung T, Bader N, Grune T (2007) Lipofuscin: formation, distribution, and metabolic consequences. *Annals of the New York Academy of Sciences* 1119: 97–111. <https://doi.org/10.1196/annals.1404.008> [PubMed]
 - Kim GA, Gan'shina TS, Kurza EV, Kurdyumov IN, Maslennikov DV, Mirzozian RS (2019) New cerebrovascular agent with hypotensive activity. *Research Results in Pharmacology* 5(2): 71–77. <https://doi.org/10.3897/rpharmacology.5/35392>
 - Krause DM, Wong E, Degener P, Roberts E (1980) GABA receptors in bovine cerebral blood vessels: binding studies with 3H muscimol. *Brain Research* 185(1): 51–57. [https://doi.org/10.1016/0006-8993\(80\)90669-1](https://doi.org/10.1016/0006-8993(80)90669-1) [PubMed]
 - Li J, Chen L, Guo F, Han X (2020) The effects of GABAergic system under cerebral ischemia: spotlight on cognitive function. *Neural Plasticity* 2020: 8856722. <https://doi.org/10.1155/2020/8856722> [PubMed] [PMC]
 - Marnett LJ, Prusakiewicz JJ, Kozak KR, Philip J, Kingsley PJ (2008) Compositions and methods for detecting and quantifying COX-2 activity by lipoamino acid metabolism. U.S. Patent No. 7,314,709. 1 Jan. 2008.
 - Mirzozian RS, Gan'shina TS, Kim GA, Kurza EV, Maslennikov DV, Kurdyumov IN, Turilova AI, Gorbunov AA (2019) The translational potential of experimental pharmacology for cerebrovascular disorders. *Annals of Clinical and Experimental Neurology* 13(3): 34–40. <https://doi.org/10.25692/ACEN.2019.3.538> [in Russian]
 - Mirzozian RS, Topchian AV, Kanaian AS, Balasarian MG (1998) The effect of nimodipine on a local ischemic brain lesion. *Annals of the Russian Academy of Medical Sciences [Vestnik Rossiiskoi Akademii Meditsinskikh Nauk]* 11: 46–51. [PubMed] [in Russian]
 - Mirzozian SA, Akopian VP (1967) Effect of gamma-aminobutyric acid on cerebral circulation and oxygen tension in the brain. *Farmakology and Toksikology [Farmakologiya i Toksikologiya]* 30(5): 572–574. [PubMed] [in Russian]
 - Mirzozian SA, Kazarian BA, Akopian VP (1970) Decarboxylase activity of glutamic acid in the vessels of the brain. *Reports of the Academy of Sciences of the USSR. Biological Sciences [Doklady Akademii Nauk Soyuzha Sovetskikh Sotsialisticheskikh Respublik]* 190(5): 1241–1242. [PubMed] [in Russian]
 - Mirzozian SA, Kazarian BA, Akopian VP (1974) The content and some transformations of amino acids in the tissues of the walls of the arteries of the brain. *Reports of the Academy of Sciences of the USSR [Doklady Akademii Nauk Soyuzha Sovetskikh Sotsialisticheskikh Respublik]* 214(2): 465–468. [in Russian]
 - Mirzoyan NR, Baghdasaryan NA, Alikhanyan CB, Meliksetyan VS, Baghdasaryan MG, Kukhtarova AM (2015a) The influence of mexidol and 2-ethyl-6-methyl-3-hydroxypyridine hemisuccinate on lipofuscin content in rat brain under local permanent ischemia conditions. *Experimental and Clinical Pharmacology [Eksperimentalnaya i Klinicheskaya Farmakologiya]* 78(8): 3–6. [PubMed] [in Russian]
 - Mirzoyan NR, Khostikyan NG, Stepanyan A G, Akopyan AA, Alikhanyan KB, Meliksetyan VS, Bagdasaryan NA, Gretskeya NM, Bezuglov VV (2015b) Studying neuroprotective activity of GABA conjugate with arachidonic acid under conditions of local permanent brain ischemia in rats. *Experimental and Clinical Pharmacology [Eksperimentalnaya i Klinicheskaya Farmakologiya]* 78(6): 7–11. <https://doi.org/10.30906/0869-2092-2015-78-6-7-11> [PubMed] [in Russian]
 - Mirzoyan RS, Gan'shina TS, Maslennikov DV, Kovalev GI, Zimin IA, Pyatin BM, Avdyunina NI, Kukhtarova AM, Khostikyan NG, Meliksetyan VS, Alikhanyan CB, Mirzoyan NR (2014) Cerebrovascular and neuroprotective effects of adamantane derivative. *BioMed Research International* 2014: 586501. <https://doi.org/10.1155/2014/586501> [PubMed] [PMC]

- Mirzoyan RS, Gan'shina TS, Gorbunov AA, Kurdyumov IN, Maslennikov DV, Turilova AI, Kurza EV (2017) Pharmacology of various neuromediator mechanisms of regulation of cerebral circulation. *Experimental and Clinical Pharmacology [Eksperimentalnaya i Klinicheskaya Farmakologiya]* 80(9): 35–39. [in Russian]
- Napoleone P, Erdo S, Amenta F (1987) Autoradiographic localization of the GABAA-receptor agonist [3H]muscimol in rat cerebral vessels. *Brain Research* 423(1–2): 109–115. [https://doi.org/10.1016/0006-8993\(87\)90830-4](https://doi.org/10.1016/0006-8993(87)90830-4) [PubMed]
- Park J [ed.] (2017) *Acute Ischemic Stroke*. Springer, Singapore, 270 pp.
- Parmar N, Ho W-SV (2010) N-arachidonoyl glycine, an endogenous lipid that acts as a vasorelaxant via nitric oxide and large conductance calcium-activated potassium channels. *British Journal of Pharmacology* 160(3): 594–603. <https://doi.org/10.1111/j.1476-5381.2009.00622.x> [PubMed] [PMC]
- Raboune S, Stuart JM, Leishman E, Takacs SM, Rhodes B, Basnet A, Jameyfield E, McHugh D, Widlanski T, Bradshaw HB (2014) Novel endogenous N-acyl amides activate TRPV1-4 receptors, BV-2 microglia, and are regulated in brain in an acute model of inflammation. *Frontiers in Cellular Neuroscience* 8: 195. <https://doi.org/10.3389/fncel.2014.00195> [PubMed] [PMC]
- Schwartz-Bloom RD, Sah R (2001) Gamma-Aminobutyric acid (A) neurotransmission and cerebral ischemia. *Journal of Neurochemistry* 77(2): 353–371. <https://doi.org/10.1046/j.1471-4159.2001.00274.x> [PubMed]
- Shafie M, Yu W (2021) Recanalization therapy for acute ischemic stroke with large vessel occlusion: Where we are and what comes next? *Translational Stroke Research* 12(3): 369–381. <https://doi.org/10.1007/s12975-020-00879-w> [PubMed] [PMC]
- Shimamura M, Zhou P, Casolla B, Qian L, Capone C, Kurinami H, Iadecola C, Anrather J (2013) Prostaglandin E2 type 1 receptors contribute to neuronal apoptosis after transient forebrain ischemia. *Journal of Cerebral Blood Flow and Metabolism* 33(8): 1207–1214. <https://doi.org/10.1038/jcbfm.2013.69> [PubMed] [PMC]
- Silkina IV, Zenina TA, Seredenin SB, Mirzoyan RS (2006) Effect of afobazole on the accumulation of free radical oxydation products and the catalase activity in rats with cerebral ischemia. *Experimental and Clinical Pharmacology [Eksperimentalnaya i Klinicheskaya Farmakologiya]* 69(4): 47–50. [PubMed] [in Russian]
- Tamura A, Graham ID, McCulloch J, Teasdale GM (1981) Focal cerebral ischemia in the rat: 1. Description of technique and early neuropathological consequences following middle artery occlusion. *Journal of Cerebral Blood Flow and Metabolism* 1(1): 53–60. <https://doi.org/10.1038/jcbfm.1981.6> [PubMed]
- Terman A, Brunk UT (2004) Lipofuscin. *International Journal of Biochemistry and Cell Biology* 36(8): 1400–1404. <https://doi.org/10.1016/j.biocel.2003.08.009> [PubMed]
- Topchian AV, Mirzoyan RS, Balasanian MG (1996) Local cerebral ischemia in rats induced by ligation of the middle cerebral artery. *Experimental and Clinical Pharmacology [Eksperimentalnaya i Klinicheskaya Farmakologiya]* 59(5): 62–64. [PubMed] [in Russian]
- Vasilieva TM, Makarov VA, Gnezdilova AV, Bezuglov VV, Gretskaia NM (2010) Effect of GABA conjugate with arachidonic acid on platelet aggregation ability and cerebral blood circulation. 5th International Conference "Biological Foundations of Individual Sensitivity to Psychotropic Drugs", Folium Publishing House, Moscow, June 1–4, 31 pp. [in Russian]
- Virani SS, Alonso A, Aparicio HJ, Benjamin EJ, Bittencourt MS, Callaway CW, Carson AP, Chamberlain AM, Cheng S, Delling FN, Elkind MSV, Evenson KR, Ferguson JF, Gupta DK, Khan SS, Kissela BM, Knutson KL, Lee CD, Lewis TT, Liu J, Loop MS, Lutsey PL, Ma J, Mackey J, Martin SS, Matchar DB, Mussolino ME, Navaneethan SD, Perak AM, Roth GA, Samad Z, Satou GM, Schroeder EB, Shah SH, Shay CM, Stokes A, Van Wagner LB, Wang NY, Tsao CW (2021) American Heart Association Council on Epidemiology and Prevention Statistics Committee and Stroke Statistics Subcommittee. Heart disease and stroke statistics-2021 update: A report from the American Heart Association. *Circulation* 143(8): e254–e743. <https://doi.org/10.1161/CIR.0000000000000950> [PubMed]
- Zhang RL, Lu CZ, Ren HM, Xiao BG (2003) Metabolic changes of arachidonic acid after cerebral ischemia-reperfusion in diabetic rats. *Experimental Neurology* 184(2): 746–752. [https://doi.org/10.1016/S0014-4886\(03\)00296-6](https://doi.org/10.1016/S0014-4886(03)00296-6) [PubMed]

Author contributions

- **Narine R. Mirzoyan**, Doctor Habil. of Medical Sciences, Professor, Head, Clinical Pharmacology Department, e-mail: nanamirzoyan@gmail.com, ORCID ID <https://orcid.org/0000-0001-5570-488X>. The author had a leading role in planning and conducting the experiments to study the neuroprotective activity of the substances, analyzing the data and the literature, and writing the article.
- **Nelly G. Khostikyan**†, Doctor Habil. of Medical Sciences, Professor, Former Head, Department of pathological anatomy and Clinical Morphology. The author participated in planning the experiments to study the neuroprotective activity of the substances, analyzing the literature, and interpreting the data.
- **Vahe S. Meliksetyan**†, Former Lecturer, Clinical Pharmacology Department. The author participated in planning the experiments to study the neuroprotective activity of the substances, analyzing the literature, and interpreting the data.
- **Arpine A. Hakobyan**, Lecturer, Clinical Pharmacology Department, e-mail: arpine.h@rambler.ru. The author participated in studying the neuroprotective activity of the substances, analyzing the literature, and interpreting the data.

- **Tamara S. Gan'shina**, Doctor Habil. of Biological Sciences, Professor, Lead Researcher, Laboratory of Pharmacology of Cerebrovascular Disorders, e-mail: toma2902@mail.ru, **ORCID ID** <https://orcid.org/0000-0003-0442-1761>. The author participated in planning the experiments to study the cerebrovascular activity of the substances, analyzing the literature, interpreting the data, and reviewing the manuscript.
- **Melanya G. Baghdasaryan**, PhD in Medical Sciences, Associate Professor, Clinical Pharmacology Department, e-mail: melanyabag@gmail.com. The author participated in planning the experiments to study the neuroprotective activity of the substances, analyzing the literature, and interpreting the data.
- **Anna M. Arakelyan**, Lecturer, Clinical Pharmacology Department, e-mail: arakelyan-machkalyan@gmail.com. The author participated in studying the neuroprotective activity of the substances, analyzing the literature, and interpreting the data.
- **Anna V. Gnezdilova**, PhD in Biological Sciences, Senior Researcher, Laboratory of Pharmacology of Cerebrovascular Disorders, e-mail: the_luxory@mail.ru, **ORCID ID** <https://orcid.org/0000-0002-8439-2683>. The author participated in planning the experiments to study the cerebrovascular activity of the substances, analyzing the literature, and interpreting the data.
- **Elena V. Kurza**, PhD in Biological Sciences, Researcher, Laboratory of Pharmacology of Cerebrovascular Disorders, e-mail: duxlink@yandex.ru, **ORCID ID** <https://orcid.org/0000-0002-5394-5839>. The author participated in planning the experiments to study the cerebrovascular activity of the substances, analyzing the literature, and interpreting the data.
- **Natalia M. Gretskaya**, Doctor Habil. of Chemical Sciences, Senior Research Worker, Laboratory of Oxylipins, e-mail: natalia.gretskaya@gmail.com. The author had a role in the compound synthesis, analyzing the data and the literature, and reviewing the manuscript.
- **Vladimir V. Bezuglov**, Doctor Habil. of Chemical Sciences, Professor, Head, Laboratory of Oxylipins, e-mail: vvbez@ibch.ru, **ORCID ID** <https://orcid.org/0000-0001-8439-8607>. The author had a role in conceptualization, analyzing the data and the literature, and reviewing the manuscript.
- **Lusine Danielyan**, Doctor Habil. of Medical Sciences, Assistant Professor, Head of Laboratory, Vice Director of the Department of Clinical Pharmacology. e-mail: lusine.danielyan@med-uni-tebingen.de, **ORCID ID** <https://orcid.org/0000-0003-4130-8477>. The author contributed to the analysis of the literature, data interpretation and article reviewing.
- **Ruben S. Mirzoyan**, Doctor Habil. of Medical Sciences, Professor, Head, Laboratory of Pharmacology of Cerebrovascular Disorders, e-mail: cerebropharm@mail.ru, **ORCID ID** <https://orcid.org/0000-0002-7542-8904>. The author had a leading role in conceptualization, planning the experiments to study the cerebrovascular activity of the substances, analyzing the data and the literature, and writing the article.