



Pharmacological correction of morphofunctional retinal injury using 11-amino acid fragment of darbepoetin in the experiment

Victoria O. Gubareva¹, Anton L. Pazhinsky², Sergey S. Lugovskoy¹, Elizaveta Yu. Dubovtsova³, Daria S. Vain⁴, Anna S. Pobeda¹, Konstantin N. Pasenov⁴

1 *St. Joseph Belgorod Regional Clinical Hospital, 8/9 Nekrasov St., Belgorod 308007 Russia*

2 *Clinic of Ambulatory Surgery Plus, LLC, 8b Shchors St., Belgorod 308027 Russia*

3 *City Hospital №2 of Belgorod, 46 Gubkin St., Belgorod 308036 Russia*

4 *Children's Regional Clinical Hospital, 44 Gubkin St., Belgorod 308036 Russia*

Corresponding author: Anna S. Pobeda (anny_87@mail.ru)

Academic editor: Oleg Gudyrev ♦ Received 1 July 2019 ♦ Accepted 25 August 2019 ♦ Published 30 September 2019

Citation: Gubareva VO, Pazhinsky AL, Lugovskoy SS, Dubovtsova EYu, Vain DS, Pobeda AS, Pasenov KN (2019) Pharmacological correction of morphofunctional retinal injury using 11-amino acid fragment of darbepoetin in the experiment. *Research Results in Pharmacology* 5(3): 43–55. <https://doi.org/10.3897/rrpharmacology.5.38730>

Abstract

Introduction: The retinoprotective effect of the 11-amino acid fragment of darbepoetin PRK-002 on the models of hypertensive retinal angiopathy and hypertensive neuroretinopathy in Wistar rats was investigated in comparison with carbamylated darbepoetin and [sulodexide](#).

Materials and methods: The protective effects of the pharmacological agents were assessed using the following criteria: a semi-quantitative assessment of changes in the eye fundus when performing ophthalmoscopy, the retinal blood flow, the b/a coefficient, eNOs expression in retinal vessels, specific number of neuronal nuclei in the inner nuclear layer, and p53 expression in the retina.

Results and discussion: A pronounced protective effect, exceeding [sulodexide](#) at a dose of 150 LRU/kg and carbamylated darbepoetin at a dose of 300 µg/kg when correcting retinal angiopathy was observed in PRK-002 at a dose of 4 µg/kg, which expressed in adjustment of the retinal vessels' calibers, removing retinal arterio-venous crossings, reaching the target levels of the retinal microcirculation, the b/a coefficient, and the restoration of eNOs expression in the endothelium of retinal vessels. PRK-002 at a dose of 4 µg/kg has a pronounced neuroprotective effect comparable to carbamylated darbepoetin at a dose of 300 µg/kg in correction of hypertensive neuroretinopathy, which expressed in the normalization of the fundus image, reaching the b/a target values, the specific number of neuronal nuclei in the inner nuclear layer, inhibition of p53 expression in the neurons of the inner nuclear and ganglionic layers.

Conclusion: The study revealed angio- and neuroprotective activity of the 11-amino acid fragment of darbepoetin PRK-002 in correction of retinal injury formed on the background of hypertension.

Keywords

11-amino acid fragment of darbepoetin, hypertensive neuroretinopathy, PRK-002, retinal angiopathy, Wistar rats.

Introduction

Hypertensive retinopathy occurs on average in 66% of patients with hypertensive disease (HD) late stages. Age, duration of HD, and systolic blood pressure (SBP) values have a significant impact on the formation of retinopathy and neuroretinopathy (Erden and Bicakci 2012).

The pathogenesis of hypertensive retinopathy is not well understood. As for today, there are three main factors in the development of hypertensive retinopathy: spasm of the retinal arteries, increased permeability of blood vessels and atherosclerosis. Among the factors of retinal angiopathy formation, there are hemodynamic disorders and local endothelial dysfunction of retinal vessels (Ivanova and Yarosheva 2008, Karaca et al. 2014). In case of endothelial dysfunction (ED), deformation of the vascular wall and stenosis of the arterioles, a complex nature of hemodynamics is formed, with areas with high and low values of shear stresses. An imbalance between intravascular (reduced perfusion pressure) and intraocular pressure is important for the development of ischemic neuropathy (Hayreh 2013). A number of studies have investigated the possibility of pharmacological correction of ED in the retina (Karaca et al. 2014, Lu et al. 2015).

In patients with pathological retinal changes on the background of arterial hypertension (AH), vascular and further neuronal changes are noted, in the pathogenesis of which the ED of retinal vessels plays an important role. Against the background of arteriospasm and arteriosclerosis, retinal ischemia is formed, which is primarily evident through pathological changes in the neurons of the retinal layers characteristic of ischemic neuropathies (Peresyphkina et al. 2018).

Hypertensive retinopathy is fraught with complications, including retinal artery occlusion, optic nerve atrophy, and retinal vein thrombosis (Kawasaki et al. 2013). Changes in retinal arterioles in HD mirror changes in brain arterioles (Hanff et al. 2014). Currently, the primary therapy of patients with hypertensive retinopathy is aimed at the normalization of blood pressure (BP) values, and the correction of the already established ischemic neuropathy.

In the treatment of retinal vein occlusions in a complex drug therapy, endothelial protector **sulodexide** is used (Avetisov et al. 2018). **Sulodexide** has antithrombotic and profibrinolytic effects. The drug is widely used to prevent cardiovascular complications in patients with diabetes mellitus (DM) (Lauver and Lucchesi 2006). Due to the introduction of **sulodexide** to the laboratory animals with experimental diabetes, correction of ED of blood vessels is observed (Tyurenkov et al. 2011).

In previous studies, it was shown that carbamylated darbepoetin at a dose of 300 µg/kg in rats increased the eNOs expression in the endothelium of retinal vessels in the correction of experimental hypertensive neuroretinopathy. In addition, inhibition of apoptosis in retinal neurons was revealed, which was confirmed by a decrease in p53 protein expression (Peresyphkina 2018).

In our opinion, a promising retinoprotector with endothelio- and neuroprotective activity can be an 11-amino

no acid fragment of darbepoetin, which has a low molecular weight compared to darbepoetin. In connection with the above, it was important to study the possibilities of pharmacological correction of morphofunctional retinal injuries using an 11-amino acid fragment of darbepoetin on models of retinal angiopathy and hypertensive neuroretinopathy.

Objective: to improve the efficacy of pharmacological correction of morphofunctional retinal injuries using an 11-amino acid fragment of darbepoetin on models of hypertensive retinal angiopathy and hypertensive neuroretinopathy.

Materials and methods

The experiments were performed in Wistar rats, males weighing 250±25 g without any external signs of the disease, which had passed quarantine. During the experiment, the rats were kept in a standard experimental biologically clean room; the air temperature was 22–24 °C; the lighting was 12 h/12 h light/dark cycle, and all the animals received granular feed and filtered water. Operations and other manipulations on rats were carried out under general anesthesia by intraperitoneal (i/p) administration of an aqueous solution of chloral hydrate. The animals were sacrificed in accordance with The European Convention for the Protection of Vertebrate Animals Used for Experimental and Other Scientific Purposes adopted by the Council of Europe (Strasbourg, France, 1986) and Council Directive 86/609/EEC of 24.11.1986 on the approximation of laws, regulations and administrative provisions of the Member States regarding the protection of animals used for experimental and other scientific purposes by an overdose of chloral hydrate administered i/p. The animals were divided into groups by stratified randomization with stratification by body weight, maintenance and feeding conditions, age, as well as operations and manipulations.

Hypertensive retinal angiopathy and hypertensive neuroretinopathy simulation

In the study, a model of hypertensive retinal angiopathy was used in male Wistar rats, in which N-nitro-L-arginine methyl ether (L-NAME) is administered daily at a dose of 12.5 mg/kg of rat weight for 28 days. In the pathogenesis of retinal angiopathy in rats, the key point is the formation of ED in the retinal vessels, the reduction of NO synthesis and the development of AH on the background of vasoconstriction.

Also, a model of hypertensive neuroretinopathy was used on male Wistar rats in the experiment, which was carried out by raising the intraocular pressure (IOP) for 5 minutes on the 26th day of the experiment, on the background of daily administration of L-NAME at a dose of 12.5 mg/kg for 28 days. One of the links in the pathogenesis of neuroretinopathy in rats is the development of hypertension against the background of NO deficiency, as well as ED of retinal vessels. Another link in the patho-

genesis is the creation of an ischemic episode in the retina with increased IOP (Peresyphkina et al. 2017).

To measure BP in rats, a non-invasive blood pressure measurement system NIBP200 was used in small animals on the tail as part of the BIOPAC SYSTEMS MP-150 complex. The results of the integrated semi-quantitative assessment of the fundus state, measurement of retinal blood flow, calculation of the b/a coefficient, immunohistochemical study of eNOs expression in the retinal layers served as confirmation of the formation of hypertensive retinal angiopathy in the experimental animals on the 29th day of the experiment.

Confirmation of the formation of hypertensive neuroretinopathy in rats on the 29th of the experiment were the results of semi-quantitative assessment of changes in the eye fundus, measurements of retinal blood flow, calculation of the b/a coefficient, the specific number of nuclei of neurons of the inner nuclear layer, and an immunohistochemical study of eNOs and p53 expression in the retinal layers.

Semi-quantitative assessment of changes in the eye fundus

To study the fundus of eye in the laboratory rats, ophthalmoscopy was used on the 29th day of the experiment, using an ophthalmoscope Bx a NEITZ, Japan. Eye drops with phenylephrine (Iridrin 2.5%, PROMED EXPORTS, India) were used for mydriasis by instillation into the conjunctival sac.

For adults, a single instillation of 2.5% solution is used during ophthalmoscopy. To create mydriasis, it is enough to inject 1 drop of 2.5% Iridrin into the conjunctival sac. One drop of eye drops Iridrin 2.5% contains 0.05 ml of the active substance. The conversion factor for an adult weighing 70 kg is 39. For rats weighing 250 g, the conversion factor is 7.0. The calculated dose of Iridrin was 0.004 ml/kg. A solution of eye drops was administered

into the conjunctival sac using a micropipette, as per the body weight of the rats.

After complete pupil dilation, the ophthalmoscope was brought closer to the rat's eye at a distance of 0.5–2 cm to obtain a clear image of the retina. To increase the possibility of obtaining photographs of the fundus, a OI-78M lens was applied (VOLK Optical Inc, Mentor, OH, USA).

For further statistical processing, the degree of changes in the fundus during ophthalmoscopy against the background of simulating and correcting retinal angiopathy and hypertensive neuroretinopathy was evaluated in points (Table 1).

Evaluation of retinal blood flow using laser Doppler flowmetry

Retinal blood flow in rats was measured by laser Doppler flowmetry (LDF) on the 29th day of the experiment (Peresyphkina et al. 2017). Registration was performed using a hardware-software complex BIOPAC SYSTEMS MP-150, a needle-type sensor TSD-144 (USA), and ACQ-KNOWLEDGE 4.2. software.

Assessment of the functional state of the retina using electroretinography (ERG)

ERG was performed immediately after recording the microcirculation level. The animals were kept in the dark for 30 minutes (Zahng et al. 2013), then anesthetized (chloral hydrate, 300 mg/kg, i/p) and fixed on a table isolated from electromagnetic radiation. The corneal silver electrode was placed on the cornea; the reference EL452 needle electrode was placed subcutaneously in the cranial region, and a ground needle electrode EL450 was placed subcutaneously at the base of the tail. A white-light stroboscope was connected to an STM200 stimulator (BIOPAC SYSTEM Inc., USA) placed behind the animal; registration of ERG was carried out in response to a single stimulat-

Table 1. Method of Semi-quantitative Assessment of Changes in the Eye Fundus When Modeling and Correcting Retinal Angiopathy and Hypertensive Neuroretinopathy, points.

Features of eye fundus changes	Score
Norm. The optic disc (OD) is round or oval, of pink colour against the background of the fundus. The boundaries of OD are clear. OD is located in the plane of the retina. The central retinal vessels emerge at the center of OD. The retinal vessels have no anastomoses. The veins and arteries are rectilinear, with no tortuosity; their caliber is uniform. The overall background is pink.	0
Angiopathy. Salus-Gunn I symptom. In the eye fundus, there is "the crossing phenomenon", which appears due to the indentation of the artery at the crossing site with the dilated vein. The vein is dilated on both sides of the crossing. Guist symptom – dilation and corkscrew tortuosity of the venules, located around the macula.	1
Angiosclerosis. Copper wire arteries. Salus-Gunn II symptom – swellings at the crossing site of the artery and the dilated vein.	2
Salus-Gunn III symptom – the disappearance of the vein at the crossing site due to its forming an arcuate curve, diving deep into the retina. Silver wire symptom. Increased vascular permeability.	3
Retinopathy. Soft exudates. Hemorrhages. In the macular zone, there may be deposits of solid star-shaped exudate.	4
Hypertensive neuroretinopathy. Obvious OD discoloration. Swollen OD and peripapillary retina. Hemorrhages and foci of soft and solid exudates, indicating increasing ischemia.	5

on. Evoked potentials were transmitted at a frequency of 1–1000 Hz, amplified, averaged and presented graphically on the screen using the BIOPAC-SYSTEMS MP-150 with ACQKNOWLEDGE 4.2. software (USA). ERG was recorded for 0.5 s in each rat in the groups. The ratio of amplitudes of b and a ERG waves to the b/a coefficient (Shabelnikova et al. 2016) was estimated to assess a degree of functional retinal damage. Out of the ten values obtained in each group, the mean was calculated to be entered into the protocol.

Assessment of retinal changes using morphometric and immunohistochemical studies

The eyes were completely removed along with the adjacent structures on the 29th day of the experiment for morphometric examination and were fixed by immersion in 10% formalin solution. After fixing, the eyes were sectioned into two parts through the centre and both halves were processed into paraffin by routine methods. Also, serial sections with a thickness of 5–7 µm were made along the meridian and stained with haematoxylin and eosin. The stages of histological processing were performed using LEICA equipment (Germany).

For microscopy, morphometry and archiving, the prepared microslides were scanned using MIRAX DESK, a computerised archiving and image analysis system. The image analysis and morphometry were carried out by PANNORAMIC VIEWER 1.15.4 software. The quantitative data were recorded in MS Excel spreadsheets.

Counting the specific number of neuronal nuclei in the inner nuclear layer was carried out by Avtandilov 's grid on standard computer images obtained by the system for scanning and archiving images MIRAX DESK and PANNORAMIC VIEWER 1.15.4 software. A computer version of the 0.3 mm² grid projected on the image was used.

An immunohistochemical (IHC) study was performed according to standard protocols with consideration of recommendations of the antibodies manufacturers. After standard deparaffinization of the sections mounted on adhesive glass slides, a high-temperature unmasking of antigens in the citrate buffer was performed. To identify the reaction, polymer detection systems ULTRA VISION (THERMOSCIENTIFIC, UK) and HISTOFINE (NICHIREI BIOSCIENCES, Japan) were used with a chromogen – diaminobenzidine.

Research design. Mode of administration and dose of pharmacological agents

The study design is presented in Table 2.

In order to correct the hypertensive retinal angiopathy, an 11-amino acid fragment of darbepoetin with laboratory code PRK-002 (PHARMAPARK LLC, Russia) in the form of lyophilized powder was dissolved in 0.5 ml of water for injection to prepare a solution with a concentration of 50 µg/ml, which was injected subcutaneously (s/c) behind the shoulder at a dose of 4 µg/kg of rat weight (recommendations of PHARMAPARK LLC) once every

Table 2. The Research Design of the Protective Effects of an 11-amino Acid Fragment of Darbepoetin PRK-002, Carbamylated Darbepoetin and Sulodexide on the Models of Hypertensive Retinal Angiopathy and Hypertensive Neuroretinopathy.

Wistar rats, males (n=90)	
1. Control group, with i/p infusion of 0.9% NaCl solution in the equivalent volume for 28 days (n=10)	
2. Simulated hypertensive retinal angiopathy (n=10)	2. Simulated hypertensive neuroretinopathy, (n=10)
3. Correction by PRK-002, 4 µg/kg (n=10)	3. Correction by PRK-002, 4 µg/kg (n=10)
4. Correction by carbamylated darbepoetin, 300 µg/kg (n=10)	4. Correction by carbamylated darbepoetin, 300 µg/kg (n=10)
5. Correction by sulodexide, 150 LRU/kg (n=10)	5. Correction by sulodexide, 150 LRU/kg (n=10)

Note: LRU – lipoprotein lipase releasing units.

3 days, starting from the first day of the experiment, 30 min before introduction of L-NAME.

The reference drug carbamylated darbepoetin in the form of an injection solution (PHARMAPARK LLC, Russia), containing 100 µg of recombinant carbamylated darbepoetin alpha in 1 ml of a solution, was administered s/c at a dose of 300 µg/kg (recommendations of PHARMAPARK LLC) once every 3 days, starting from the first day of the experiment, 30 minutes before the introduction of L-NAME in the correction of experimental retinal angiopathy (Peresyphkina 2018).

Sulodexide in the form of capsules, 250 LRU (Vessel Due F, ALFA WASSERMANN S.p.A., Italy) was administered per os for 28 days at a dose of 150 LRU/kg daily (Tyurenkov et al. 2011) in order to correct the experimental hypertensive retinal angiopathy as a comparison drug.

When studying the possibility of correcting hypertensive neuroretinopathy in Wistar rats, the above pharmacological agents were used at similar doses and modes of administration. The doses and modes of administration of the studied pharmacological agents are based on their efficacy in experimental studies (Tyurenkov et al. 2012).

The efficacy of the studied agents on the models of retinal angiopathy and hypertensive neuroretinopathy was evaluated on the 29th day of the experiment using ophthalmoscopy, semi-quantitative assessment of changes in the eye fundus, LDF, ERG, morphometric and immunohistochemical studies.

Statistical data processing

For all data, descriptive statistics were used, and the data were checked for normal distribution. The distribution type was determined by using the Shapiro-Wilk criterion. In case of normal distribution, the mean (M) and standard error of the mean (m) were calculated. The outliers at each time point were identified using Grubbs' statistical test. If for some value, the Z was greater than the critical value for a given number of measurements (N), this experiment was excluded from further calculations. In cases of abnormal distribution, the median (Me) and the quar-

tile range (QR) were calculated. Between-group differences were analyzed by parametric (t-Student criterion) or non-parametric (Mann-Whitney test) methods, depending on the type of distribution. Differences were determined at a 0.05 significance level. The statistical analyses were performed using STATISTICA 10.0 software.

Results and discussion

Evaluation of the efficacy of PRK-002, carbamoylironium darbepoetin and sulodexide in the correction of experimental hypertensive angiopathy of the retina

This study included 50 Wistar male rats, weighing 225–275 g. A model of hypertensive retinal angiopathy was used, the pathogenesis of which was associated with the development of hypertension in rats on the background of daily i/p administration of L-NAME at a dose of 12.5 mg/kg for 28 days.

In the control group, SBP was 129.5±9.1 mm Hg, and DBP was 92.3±7.2 mm Hg. In the group with administration of L-NAME, when simulating retinal angiopathy, SBP was 203.6±12.1 mm Hg. ($p < 0.05$ in comparison with the control group), and DBP was 162.5±9.8 mm Hg ($p < 0.05$ in comparison with the control group). The results of blood pressure measurements in groups with the introduction of the studied pharmacological agents and reference drugs are presented in Table 3.

Against the background of injecting PRK-002 at a dose of 4 µg/kg, a moderate decrease was observed in SBP – by 22.3% ($p < 0.05$ in comparison with the group with the pathology simulation) and in DBP – by 29.1% ($p < 0.05$ in comparison with the group with the pathology simulation). It should be noted that the values of SBP and DBP in the group with the introduction of PRK-002 do not reach

Table 3. Influence of PRK-002, Carbamylated Darbepoetin and Sulodexide on Systolic and Diastolic Blood Pressure in Rats on 29th Day of the Experiment in Correction of Hypertensive Retinal Angiopathy (M±m; n=10), mm Hg.

Experimental groups	SBP (mm Hg)	DBP (mm Hg)
1. Control	129.5±9.1	92.3±7.2
2. Simulated hypertensive retinal angiopathy	203.6±12.1*	162.5±9.8*
3. Correction by PRK-002, 4 µg/kg	158.1±11.5* ^y	115.2±8.2* ^y
4. Correction by carbamylated darbepoetin, 300 µg/kg	190.3±11.6*	150.7±8.9*
5. Correction by sulodexide, 150 LRU/kg	200.5±10.4*	152.0±7.9*

Note: SBP – systolic blood pressure, DBP – diastolic blood pressure. * – $p < 0.05$ in comparison to the control group; ^y – $p < 0.05$ in comparison to the group with pathology simulation.

the target values. The moderate hypotensive effect of PRK-002 is likely to be associated with an increased eNOs activity and increased NO synthesis. In the groups with the introduction of carbamylated darbepoetin at a dose of 300 µg/kg, as well as sulodexide at a dose of 150 LRU/kg, there was no significant decrease in SBP and DBP in comparison with the group with the pathology simulation. In the group with the introduction of carbamylated darbepoetin, there was a slight decrease in SBP and DBP in comparison with the group with the pathology simulation.

On the 29th day of the experiment, the rats in all groups were anesthetized to perform ophthalmoscopy. An example of an image of the eye fundus of a Wistar rat of the control group is shown in Figure 1A and has the following description: OD is round or oval; the color of OD is pale pink; its boundaries are clear. OD lies in the plane of

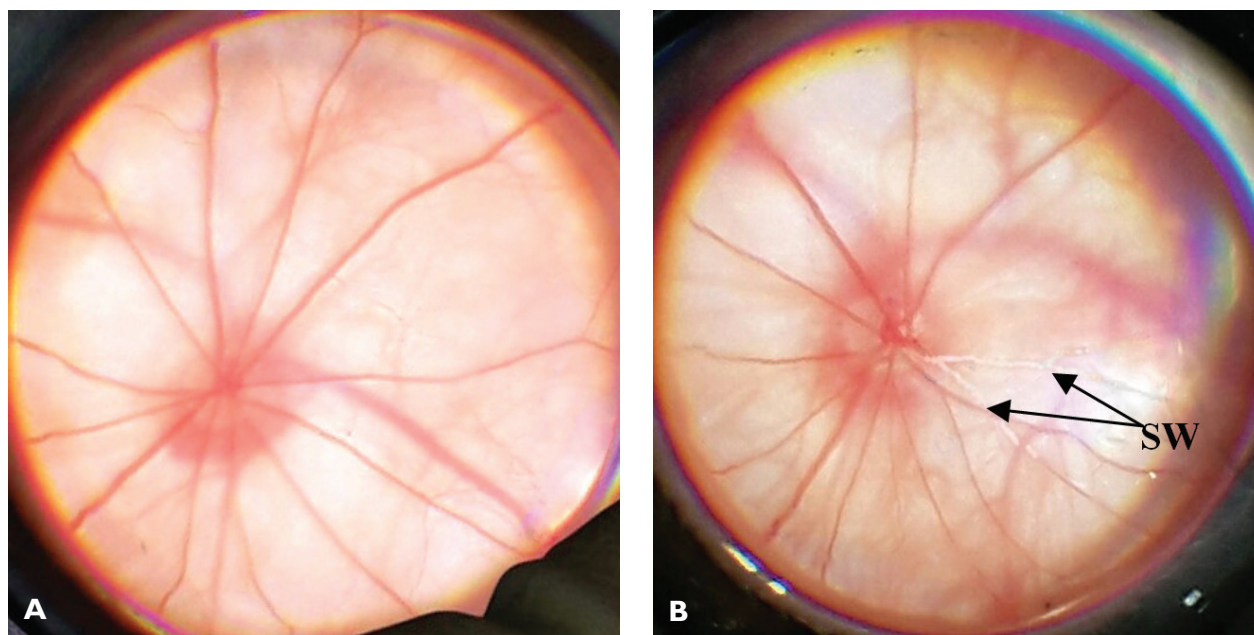


Figure 1. Eye fundus images of Wistar rats: **A** – from the control group; **B** – with the simulated hypertensive retinal angiopathy. **Note:** SW – silver wire symptom.

the retina; the retina adheres firmly to the choroid. Retinal vessels are rectilinear; the caliber is uniform, and there is no tortuosity. The general background of the retina is pink.

An example of the image of the eye fundus of a Wistar rat in the simulation of retinal angiopathy is shown in Figure 1B and has the following description: OD is round or oval and stands out against the general background of the retina with its pink colour. Its boundaries are clear. Veins are dilated. Arteries are narrowed (filamentous). There are arterio-venous crosses and the silver wire symptom.

The ophthalmoscopic image in the correction of retinal angiopathy by PRK-002 at a dose of 4 µg/kg is shown in Figure 2A and has a description close to the norm: OD is round or oval and stands out against the fundus with its pale pink colour. OD has clear boundaries and lies in the plane of the retina. Retinal vessels are rectilinear, there is no tortuosity of veins. The general background of the retina is pink.

The observed protective effect in the eye fundus of Wistar rats with the injection of PRK-002 may be asso-

ciated with eNOs activation and increased NO synthesis in blood vessels of the retina, which eventually leads to vasodilation of the retinal arteries.

When carbamylated darbepoetin at a dose of 300 µg/kg is administered to rats for the correction of retinal angiopathy, there is venous plethora, arterial spasm, and vascular tortuosity (Fig. 2B).

When injecting sulodexide at a dose of 150 LRU/kg, the eye fundus image is close to normal; there is still a slight spasm of the retinal arteries, but no arteriovenous crosses were noted (Fig. 2C). The protective effect of sulodexide on the fundus in the correction of L-NAME-induced retinal angiopathy is likely to be associated with endothelium-dependent vasodilation of retinal vessels.

The results of a semi-quantitative assessment of the fundus state in the experimental groups are presented in Table 4.

Based on the data of the semi-quantitative assessment of changes in the eye fundus on the model of hypertensive retinal angiopathy, it follows that the studied drugs have a

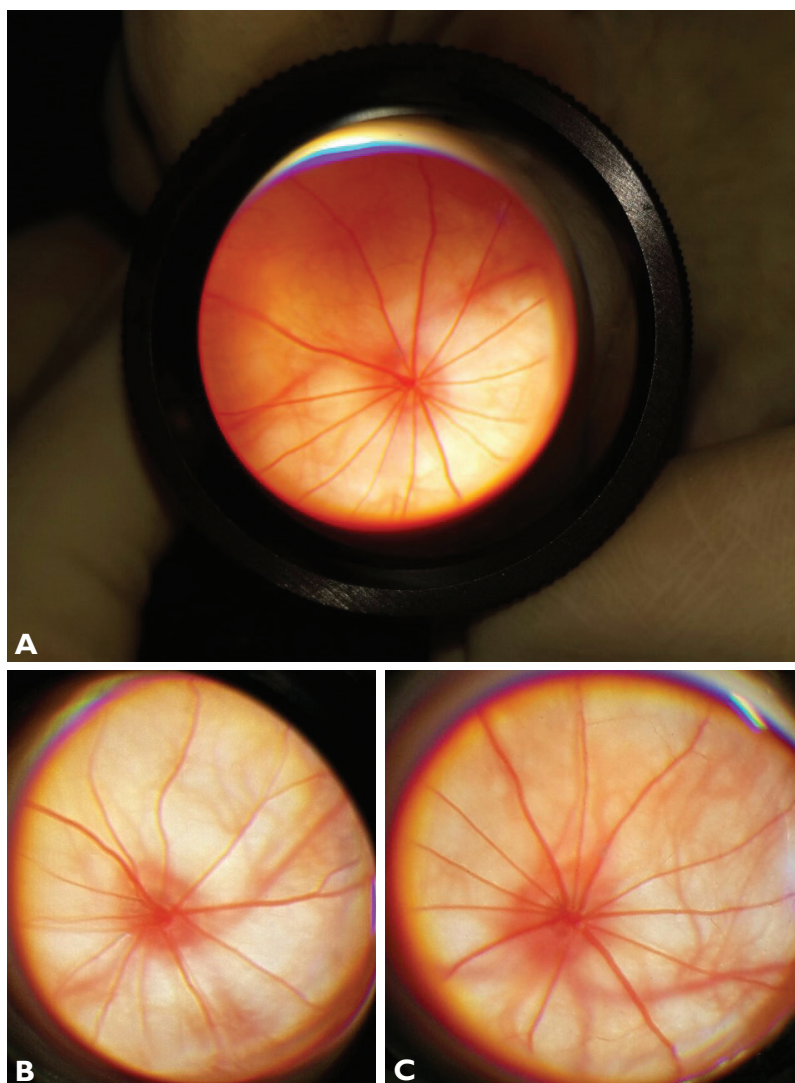


Figure 2. Eye fundus image of rats with correction of hypertensive retinal angiopathy by: A – PRK-002 at a dose of 4 µg/kg, B – carbamylated darbepoetin at a dose of 300 µg/kg, C – sulodexide at a dose of 150 LRU/kg.

Table 4. Influence of PRK-002, Carbamylated Darbepoetin and Sulodexide on the Results of Semi-quantitative Assessment of Changes in the Eye Fundus in Correction of Hypertensive Retinal Angiopathy (M±m; n=10), points.

Experimental groups	Score
1. Control	0.2±0.1
2. Simulated hypertensive retinal angiopathy	3.2±0.1*
3. Correction by PRK-002, 4 µg/kg	0.3±0.2 ^y
4. Correction by carbamylated darbepoetin, 300 µg/kg	0.8±0.2 ^y
5. Correction by sulodexide, 150 LRU/kg	0.5±0.2 ^y

Note: * – $p < 0.05$ in comparison to the control group; ^y – $p < 0.05$ in comparison to the group with pathology simulation.

protective effect in the descending order: PRK-002, 4 µg/kg > sulodexide, 150 LRU/kg > carbamylated darbepoetin, 300 µg/kg.

In the group with the simulated retinal angiopathy, the level of retinal blood flow decreased by 41.9% ($p < 0.05$) compared to the mean value in the control group. When correcting the pathology by means of PRK-002 at a dose of 4 µg/kg, the blood flow level increased by 68.6% ($p < 0.05$) compared to the group without correction and did not differ significantly from the mean value of the control group. The correction of the pathology by carbamylated darbepoetin at a dose of 300 µg/kg, the level of the microcirculation increased by 24.1% ($p < 0.05$) in comparison with the group without correction, but did not reach the target values. When correcting with sulodexide at a dose of 150 LRU/kg, the level of microcirculation increased by 63.1% ($p < 0.05$) compared to the mean value in the group without correction of the pathology.

Based on the assessment data of the microcirculation level in the retina in the experimental groups, it follows that the studied drugs positively influence the condition of retinal blood flow in the descending order: PRK-002, 4 µg/kg > sulodexide, 150 LRU/kg > carbamylated darbepoetin, 300 µg/kg. Presumably, the activation of eNOs in retinal vessels in the correction of hypertensive retinal angiopathy by means of the investigated pharmacological agents leads to endothelium-dependent vasodilation, resulting in marked positive dynamics of microcirculation in the retina.

In each group, the b/a coefficient was calculated, the values of which are presented in Table 5.

Thus, based on the obtained values of the b/a coefficient in the experimental groups, it follows that the studied drugs have a positive effect on the electrophysiological state of the retina in the correction of hypertensive retinal angiopathy in descending order: PRK-002, 4 µg/kg > sulodexide, 150 LRU/kg > carbamylated darbepoetin, 300 µg/kg.

IHC studies revealed a marked decrease in the eNOs expression in the blood vessels of the retina in the simulated hypertensive retinal angiopathy in comparison with the images in the control group. In the control group, eNOs expression was observed at the level of the ganglionic layer, namely in the endothelium of the retinal vessels, as well as in the capillaries at the level of the outer retinal

Table 5. Influence of PRK-002, Carbamylated Darbepoetin and Sulodexide on the b/a Coefficient When Correcting Hypertensive Retinal Angiopathy (M±m; n=10), R.U.

Experimental groups	b/a
1. Control	2.60±0.07
2. Simulated hypertensive retinal angiopathy	2.20±0.13*
3. Correction by PRK-002, 4 µg/kg	2.50±0.12 ^y
4. Correction by carbamylated darbepoetin, 300 µg/kg	2.40±0.07
5. Correction by sulodexide, 150 LRU/kg	2.50±0.10 ^y

Note: * – $p < 0.05$ in comparison to the control group; ^y – $p < 0.05$ in comparison to the group with pathology simulation.

layer. In the experimental groups, on the background of correction of retinal angiopathy by means of PRK-002 at a dose of 4 µg/kg; carbamylated darbepoetin at a dose of 300 µg/kg; and sulodexide at a dose of 150 LRU/kg, eNOs expression was restored in the vascular endothelium at the level of the ganglionic layer, the outer retinal layer (Fig. 3).

Thus, the result of IHC revealed that the correction of the hypertensive retinal angiopathy by PRK-002 at a dose of 4 µg/kg; by carbamylated darbepoetin at a dose of 300 µg/kg; or by sulodexide at a dose of 150 LRU/kg restored the eNOs expression in the endothelium of the retinal vessels and capillaries of the outer retinal layer, indicating recovery of endothelial function in the retinal vessels.

The results of a complex analysis, including an integral semi-quantitative assessment of the eye fundus during ophthalmoscopy, measurement of retinal microcirculation, quantitative assessment of the functional state of the retina, the results of IHC studies on the 29th day of the experiment, revealed that the most pronounced protective effect, superior to that of the reference drugs sulodexide at a dose of 150 LRU/kg and carbamylated darbepoetin at a dose of 300 µg/kg in the correction of experimental retinal angiopathy, is characteristic of an 11-amino acid fragment of darbepoetin PRK-002 at a dose of 4 µg/kg, which is reflected in the adjustment of the retinal vessels calibers, elimination of arterio-venous crosses in the retina, reaching the target values of the level of microcirculation in the retina, and the b/a coefficient, restoration of eNOs expression in the vascular endothelium at the level of the ganglionic layer and the outer retinal layer.

Evaluation of the efficacy of PRK-002, carbamylated darbepoetin and sulodexide in the correction of experimental hypertensive neuroretinopathy

This study included 50 Wistar male rats, weighing 225–275 g. In the control group, SBP was 129.5±9.1 mm Hg and DBP was 92.3±7.2 mm Hg. In the group with the injection of L-NAME when simulating hypertensive neuroretinopathy, SBP was 198.5±14.3 mm Hg ($p < 0.05$ in comparison with the control group) and DBP was 156.1±10.3 mm Hg.art. ($p < 0.05$ in comparison with the control group). Against the background of the injection of PRK-002 at a dose of 4 µg/kg, there was a moderate

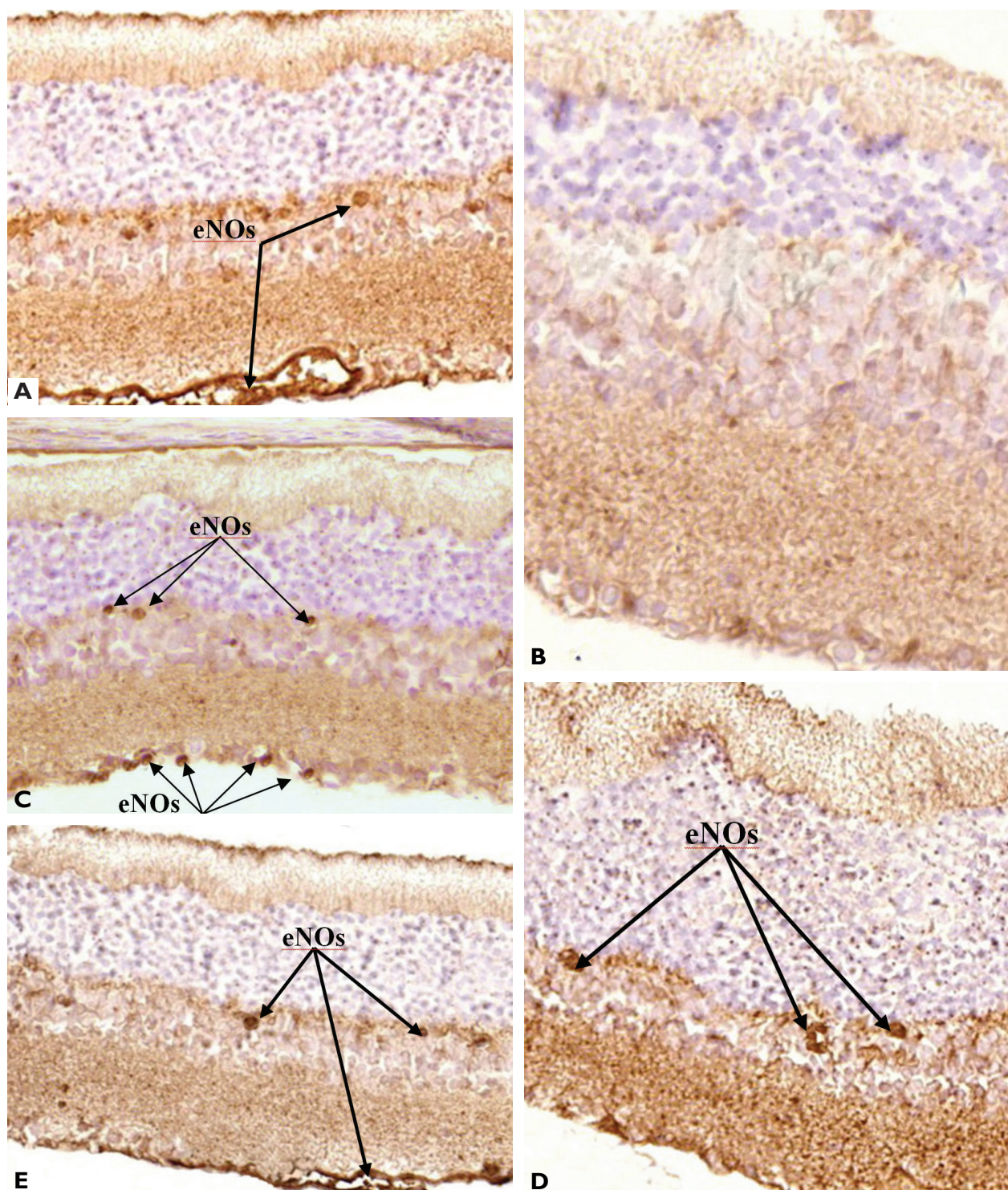


Figure 3. Examples of eNOs expression in the retina of rats: **A** – from control group, **B** – with retinal angiopathy simulation, **C** – with the correction of retinal angiopathy by PRK-002 at a dose of 4 µg/kg, **D** – with the correction by carbamylated darbepoetin at a dose of 300 µg/kg, **E** – with the correction by sulodexide at a dose of 150 LRU/kg. Immunohistochemical reaction. Microphoto. x100. **Note:** the arrows indicate the vessels with a pronounced eNOs expression.

decrease in SBP by 22.4%, $p < 0.05$ and DBP – by 26.9%, $p < 0.05$ in comparison with the group with the model of pathology. The values of SBP and DBP in the group with the injection of PRK-002 did not reach the target values. In the groups with the injection of carbamylated darbepoetin at a dose of 300 µg/kg and **sulodexide** at a dose of

150 LRU/kg, there was no significant decrease in BP in comparison with the group with the model of pathology. In the group with the injection of carbamylated darbepoetin, there was a slight decrease in BP in comparison with the group with the model of pathology.

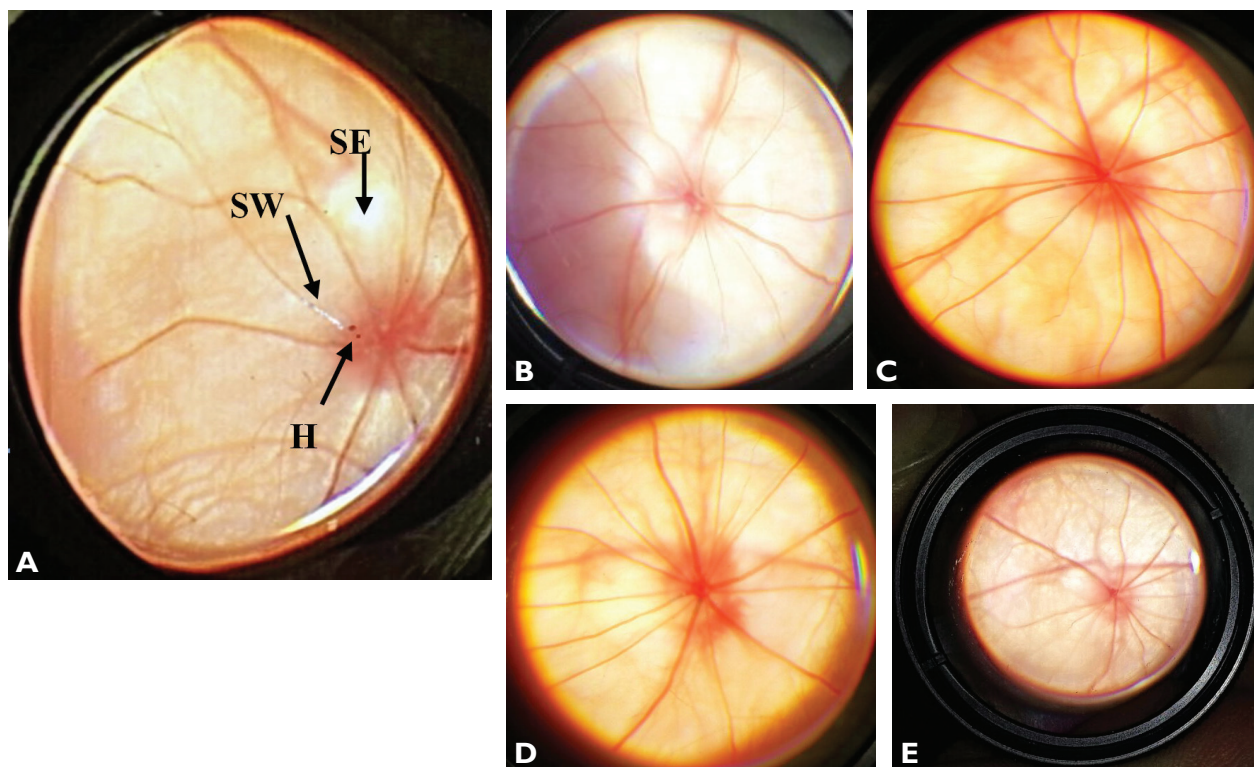


Figure 4. The image of the eye fundus of the rat: **A, B** – with hypertensive neuroretinopathy model, **C** – with the injection of PRK-002 at a dose of 4 µg/kg, **D** – with the injection of carbamylated darbepoetin at a dose of 300 µg/kg, **E** – with the injection of sulodexide at a dose of 150 LRU/kg. **Note:** H – hemorrhage, SE – soft exudate, SW – of silver wire symptom.

The eye fundus image in rats with hypertensive neuroretinopathy model is the following: OD is edematous and enlarged. The boundaries of OD are not clear. There are foci of soft exudate. The veins are full and tortuous in the periphery. Gunn’s crossing sign. Silver wire symptom. Spot hemorrhages (Fig. 4A). The ophthalmoscopic image in the correction of hypertensive neuroretinopathy by PRK-002 at a dose of 4 µg/kg is shown in Figure 4B and has a description close to the norm. On the background of the correction of pathology by carbamylated darbepoetin, there is slight venous congestion. The state of OD is close to normal. The general background is pink (Fig. 4C). The observed protective effect in the eye fundus with the injection of PRK-002 and carbamylated darbepoetin on the model of hypertensive neuroretinopathy may be associated with the activation of eNOs in blood vessels of the retina and inhibition of p53 expression in neurons of the retina. Against the background of the injection of sulodexide at a dose of 150 LRU/kg, a small spasm of the retinal arteries remains; there are no arterio-venous crosses; OD is edematous, and the edema spreads to the retina. The retina is pale (Fig. 4G).

The results of the semi-quantitative assessment of changes in the eye fundus in the experimental groups are presented in Table 6.

Based on the obtained data of the semi-quantitative assessment of changes in the eye fundus on the model of hypertensive neuroretinopathy, it follows that the substances have the protective effect in descending order: PRK-002,

Table 6. Influence of PRK-002, Carbamylated Darbepoetin and Sulodexide on the Results of Semi-quantitative Assessment of Changes in the Eye Fundus in Correction of Hypertensive Neuroretinopathy (M±m; n=10), points.

Experimental groups	Score
1. Control	0.2±0.1
2. Simulated hypertensive neuroretinopathy	4.9±0.1*
3. Correction by PRK-002, 4 µg/kg	0.2±0.2 ^y
4. Correction by carbamylated darbepoetin, 300 µg/kg	0.1±0.1 ^y
5. Correction by sulodexide, 150 LRU/kg	4.5±0.3*

Note: * – $p < 0.05$ in comparison to the control group; ^y – $p < 0.05$ in comparison to the group with pathology simulation.

4 µg/kg (carbamylated darbepoetin, 300 µg/kg) > sulodexide, 150 LRU/kg.

The results of the LDF are presented in Table 7.

Based on the obtained data of the assessment the microcirculation level in the retina in the experimental groups on the hypertensive neuroretinopathy model, it follows that the substances have a positive effect on the state of retinal blood flow in descending order: PRK-002, 4 µg/kg > sulodexide, 150 LRU/kg > carbamylated darbepoetin, 300 µg/kg.

In each experimental group, the coefficient b/a was calculated, the values of which are presented in Table 8.

Thus, based on the obtained values of the b/a coefficient in the experimental groups, it follows that the substances have a positive effect on the electrophysiological

Table 7. Influence of PRK-002, Carbamylated Darbepoetin and Sulodexide on the Level of Retinal Microcirculation When Correcting Simulated Hypertensive Neuroretinopathy (M±m), perfusion units.

Experimental groups	Level of microcirculation, P.U.
1. Control	743.0±20.9
2. Simulated hypertensive neuroretinopathy	417.2±13.1*
3. Correction by PRK-002, 4 µg/kg	704.5±21.1 ^y
4. Correction by carbamylated darbepoetin, 300 µg/kg	592.4±9.6* ^y
5. Correction by sulodexide, 150 LRU/kg	636.4±19.8* ^y

Note: P.U. – perfusion units; * $p < 0.05$ compared to the control group; ^y $p < 0.05$ compared to the group with simulated hypertensive neuroretinopathy.

Table 8. Influence of PRK-002, Carbamylated Darbepoetin and Sulodexide on the Values of the b/a Coefficient When Correcting Simulated Hypertensive Neuroretinopathy (M±m; n=10), R.U.

Experimental groups	b/a
1. Control	2.60±0.07
2. Simulated hypertensive neuroretinopathy	1.91±0.08*
3. Correction by PRK-002, 4 µg/kg	2.50±0.13 ^y
4. Correction by carbamylated darbepoetin, 300 µg/kg	2.51±0.06 ^y
5. Correction by sulodexide, 150 LRU/kg	2.31±0.10* ^y

Note: * – $p < 0.05$ in comparison to the control group; ^y – $p < 0.05$ in comparison to the group with pathology simulation.

state of the retina in the correction of hypertensive neuroretinopathy in descending order: PRK-002, 4 µg/kg (carbamylated darbepoetin, 300 µg/kg) > sulodexide, 150 LRU/kg.

The results of the counting of the specific number of neuronal nuclei in the inner nuclear layer in the experimental groups are presented in Table 9.

A neuroprotective activity in relation to neurons of the inner nuclear layer of the retina is expressed almost equally in PRK-002 at a dose of 4 µg/kg and in carbamylated darbepoetin at a dose of 300 µg/kg, significantly exceeding the activity of sulodexide at a dose of 150 LRU/kg on the model of hypertensive neuroretinopathy.

The IHC study revealed a pronounced decrease in the eNOs expression in the retinal vessels in a hypertensive neuroretinopathy simulation in comparison with the images of the control group. In the experimental groups on the background of correction of hypertensive neuroretinopathy by PRK-002 at a dose of 4 µg/kg; carbamylated darbepoetin at a dose of 300 µg/kg; or sulodexide at a dose of 150 LRU/kg, the eNOs expression returned to normal in vascular endothelium at the level of the ganglionic layer and the outer retinal layer. In the group with pathology simulation, there was activation of apoptosis, as evidenced by an increase in the expression of p53 protein in neurons of the retina. On the background of correction by PRK-002; carbamylated darbepoetin, a decrease in the p53 expression was observed, which indicated the

Table 9. Influence of PRK-002, Carbamylated Darbepoetin and Sulodexide on the Specific Number of Neuronal Nuclei in the Inner Nuclear Layer When Correcting Simulated Hypertensive Neuroretinopathy (M±m; n=10), absolute units.

Experimental groups	Number of nuclei
1. Control	12.8±0.9
2. Simulated hypertensive neuroretinopathy	8.5±0.7*
3. Correction by PRK-002, 4 µg/kg	12.1±0.9 ^y
4. Correction by carbamylated darbepoetin, 300 µg/kg	11.7±0.8 ^y
5. Correction by sulodexide, 150 LRU/kg	9.2±0.7*

Note: * – $p < 0.05$ in comparison to the control group; ^y – $p < 0.05$ in comparison to the group with pathology simulation.

inhibition of apoptosis in the retina. When correcting the pathology by sulodexide, there was no decrease in the p53 expression in the neurons of the retina.

The results of a complex analysis, including an integral semi-quantitative assessment of the eye fundus changes during ophthalmoscopy, measurement of retinal microcirculation, quantitative assessment of the functional state of the retina, the results of counting the specific number of nuclei of neurons of the inner nuclear layer, IHC studies on the 29th day of the experiment, revealed that the most pronounced neuroprotective effect comparable to the reference drug carbamylated darbepoetin at a dose of 300 µg/kg in the correction of experimental hypertensive neuroretinopathy was observed in PRK-002 at a dose of 4 µg/kg, which expressed in reaching the target values of the b/a coefficient, the specific number of neuronal nuclei in the inner nuclear layer, and inhibition of p53 protein expression in the neurons of the inner nuclear and ganglionic layers.

Against the background of correction of hypertensive neuroretinopathy by carbamylated darbepoetin at a dose of 300 µg/kg, the level of microcirculation does not reach the target values, while the correction by PRK-002 at a dose of 4 µg/kg restores the blood flow level to the values of the control group.

On the background of correction of the pathology by sulodexide at a dose of 150 LRU/kg, there happens mainly the correction of vascular changes of the retina, without any significant effect on the state of the neurons of the retina.

Among the pharmacological strategies for the correction of retinal injuries, of interest is the use of low molecular weight derivatives of darbepoetin for cytoprotection, realized through the activation of heterodimer receptors to erythropoietin, and for endothelioprotection of retinal vessels (Peresyphkina et al. 2018).

The evidence of potential erythropoietin receptors that can mediate the protective function of erythropoietin with an emphasis on the nervous system is summarized. In particular, in addition to EpoR, three other potential neuroprotective Epo receptors are discussed: (1) a heteroreceptor consisting of EpoR and a common beta receptor (βcR), (2) an ephrin receptor (Eph) B4, and (3) a CRLF3 receptor (Ostrowski and Heinrich 2018). βcR is associated with EpoR, forming an Epo-sensitive protective het-

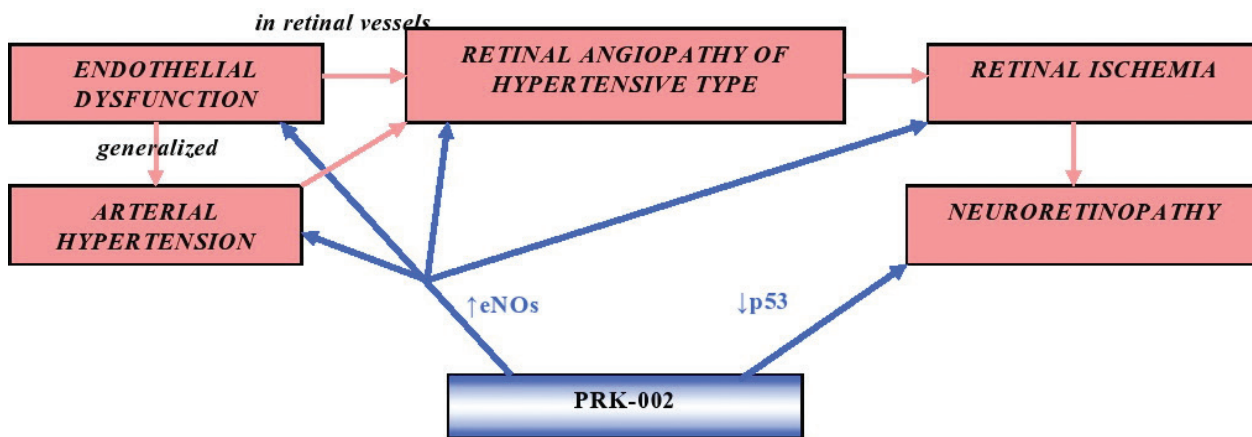


Figure 5. Hypothetical mechanism of protective action of PRK-002 at a dose of 4 $\mu\text{g}/\text{kg}$ in the hypertensive retinal angiopathy and hypertensive neuroretinopathy simulation.

eroreceptor (Bennis et al. 2012, Cendrowski et al. 2016). Selective activation of heterodimeric EpoR/ βcR , rather than homodimeric EpoR, was demonstrated for carbamylated erythropoietin, peptides originating from or associated with helix-B Epo (Brines 2010).

There were reports about neuroprotective effects of NeuroEPO, a low-sialic form of erythropoietin, on oxidative stress caused by excitotoxicity of glutamate. The effect of NeuroEPO on apoptosis caused by excitotoxicity of glutamate in primary cultures of neurons derived from the anterior brain of Wistar rat embryos after 17 days of pregnancy was analyzed. Excitotoxicity was induced after nine days of *in vitro* cultivation by treatment with a culture medium containing 100 μm glutamate for 15 minutes. Apoptosis was analyzed after 24 hours. It was shown that neurons treated with glutamate exhibited loss of dendrites that did not come into contact with the neighboring cells, and that NeuroEPO was able to maintain the morphological characteristics of the control. The images of immunocytochemistry show that glutamate causes cell death, and this is partially avoided when NeuroEPO is added to the culture medium. The activation of internal apoptotic pathways was analyzed. The reduced Bcl-2/Bax ratio, increased cytochrome C Release, and the expression and activity of caspase-3 observed in glutamate-treated cells were restored by NeuroEPO. The results of this study show that NeuroEPO protects cortical neurons from glutamate-induced apoptosis by activating Bcl-2 and inhibits glutamate-induced activation of caspase-3 (Garzón et al. 2018).

The results of this study provide a theoretical justification for new possibilities of correction of vascular and neuronal retinal injuries on the background of AH, aimed at: correction of local ED of retinal vessels; correction of generalized ED and, as a consequence, a moderate decrease in BP; and inhibition of p53 protein expression in retinal neurons. The hypothetical mechanism of realization of protective effects of an 11-amino acid fragment of darbepoietin on models of retinal angiopathy and hypertensive neuroretinopathy is presented in Figure 5.

Conclusion

The results of this study are the following:

1. A pronounced protective action, superior to that of the reference drugs *sulodexide* at a dose of 150 LRU/kg and carbamylated darbepoietin at a dose of 300 $\mu\text{g}/\text{kg}$ in the correction of hypertensive retinal angiopathy in Wistar rats, is revealed in an 11-amino acid fragment of darbepoietin PRK-002 at a dose of 4 $\mu\text{g}/\text{kg}$, which is expressed in the adjustment of the caliber of retinal vessels, elimination of arterio-venous crosses in the retina, reaching the target values of the microcirculation level in the retina, the b/a coefficient, restoration of eNOs expression in the vascular endothelium at the level of the ganglionic layer and the outer retinal layer.
2. A protective effect on the model of hypertensive retinal angiopathy, inferior to that of PRK-002 at a dose of 4 $\mu\text{g}/\text{kg}$, is revealed in carbamylated darbepoietin at a dose of 300 $\mu\text{g}/\text{kg}$, which is expressed in a significant 75% decrease ($p < 0.05$) in scores of the semi-quantitative assessment of the fundus state, detected in ophthalmoscopy, compared with the mean value of the group without correction of the pathology; restoration of eNOs expression in the endothelium of retinal vessels at the level of the ganglionic layer and the outer retinal layer. The target values of the microcirculation level in the retina and the b/a coefficient in the group with the injection of carbamylated darbepoietin are not reached.
3. A protective effect in the hypertensive retinal angiopathy simulation, inferior to that of PRK-002 at a dose of 4 $\mu\text{g}/\text{kg}$, is revealed in *sulodexide* at a dose of 150 LRU/kg, resulting in a significant 84% decrease ($p < 0.05$) in scores of the semi-quantitative assessment of the fundus state revealed by ophthalmoscopy in comparison with the mean value of the group without the pathology correction; a sig-

nificant 63% increase in the microcirculation level in the retina ($p < 0.05$) in comparison with the mean value in the group without correction; reaching the target values of b/a; and the restoration of eNOs expression in the endothelium of retinal vessels.

4. The results of a complex analysis, including an integral semi-quantitative assessment of the eye fundus state, measuring the level of retinal microcirculation, quantitative assessment of the functional state of the retina, the results of morphometric and IHC studies, revealed that the most pronounced neuroprotective effect, comparable to that of carbamylated darbepoethin at a dose of 300 $\mu\text{g}/\text{kg}$ in the correction of hypertensive neuroretinopathy in Wistar rats, is revealed in PRK-002 at a dose of 4 $\mu\text{g}/\text{kg}$, which is expressed in the normalization of the eye fundus image, reaching the target values of the b/a coefficient, specific number of neuronal nuclei in the inner nuclear layer, inhibition of p53 protein expression in neurons of the inner nuclear and ganglionic layers. The microcirculation level in the retina in the group with the injection of PRK-002 at a dose of 4 $\mu\text{g}/\text{kg}$ reaches the target values; there is a restoration of eNOs expression in the retinal vessels.
5. Against the background of correction of hypertensive neuroretinopathy by carbamylated darbepoethin at a dose of 300 $\mu\text{g}/\text{kg}$, normalization of the eye fundus image is observed, but the microcirculation level does not reach the target values; the values of the b/a coefficient and the specific number of neuronal nuclei in the inner nuclear layer in the group do not differ significantly from the norm; eNOs expression is restored in the endothelium of retinal vessels and capillaries of the outer retinal layer, which indicates the restoration of the endothelium function of the retina; inhibition of p53 expression is observed in retinal neurons.
6. On the background of the correction of hypertensive neuroretinopathy by **sulodexide** at a dose of 150 LRU/kg, mainly correction of vascular changes in the retina is observed, probably due to restoration of eNOs expression in the endothelium of retinal vessels, without significant effect on the state of the neurons of the retina.

Conflicts of interest

The authors have no conflict of interest to declare.

References

- Avetisov SE, Egorov EA, Moshetova LK, Neroev VV, Tahchidi HP (2018) Ophthalmology: National Guidance. GEOTAR-Media, Moscow, 904 pp. [in Russian]
- Bennis Y, Sarlon-Bartoli G, Guillet B, Lucas L, Pellegrini L, Velly L, Blot-Chabaud M, Dignat-Georges F, Sabatier F, Pisano P (2012) Priming of late endothelial progenitor cells with erythropoietin before transplantation requires the CD131 receptor subunit and enhances their angiogenic potential. *Journal of thrombosis and haemostasis* 10(9): 1914–1928. <https://doi.org/10.1111/j.1538-7836.2012.04835.x> [PubMed]
- Brines M (2010) The therapeutic potential of erythropoiesis-stimulating agents for tissue protection: A tale of two receptors. *Blood Purification* 29(2): 86–92. <https://doi.org/10.1159/000245630> [PubMed]
- Cendrowski J, Mamińska A, Miaczynska M (2016) Endocytic regulation of cytokine receptor signaling. *Cytokine & Growth Factor Reviews* 32: 63–73. <https://doi.org/10.1016/j.cytogfr.2016.07.002> [PubMed]
- Erden S, Bicakci E (2012) Hypertensive retinopathy: incidence, risk factors, and comorbidities. *Clinical and Experimental Hypertension* 34(6): 397–401. <https://doi.org/10.3109/10641963.2012.663028> [PubMed]
- Garzón F, Coimbra D, Parcerisas A, Rodríguez Y, García JC, Soriano E, Rama R (2018) NeuroEPO preserves neurons from glutamate-induced excitotoxicity. *Journal of Alzheimer's Disease* 65(4): 1469–1483. <https://doi.org/10.3233/JAD-180668> [PubMed]
- Hanff TC, Sharrett AR, Mosley TH, Shibata D, Knopman DS, Klein R, Klein BE, Gottesman RF (2014) Retinal microvascular abnormalities predict progression of brain microvascular disease: an atherosclerosis risk in communities magnetic resonance imaging study. *Stroke* 45(4): 1012–1017. <https://doi.org/10.1161/STROKEAHA.113.004166> [PubMed]
- Hayreh SS (2013) Ischemic optic neuropathies – where are we now? *Graefes's Archive for Clinical and Experimental Ophthalmology* 251(8): 1873–1884. <https://doi.org/10.1007/s00417-013-2399-z> [PubMed]
- Ivanova NV, Yarosheva NA (2008) Hemostatic imbalance and endothelial dysfunction in patients with diabetic retinopathy. *Journal of Ophthalmology* 3: 33–38. [in Russian]
- Karaca M, Coban E, Ozdem S, Unal M, Salim O, Yucel O (2014) The association between endothelial dysfunction and hypertensive retinopathy in essential hypertension. *Medical Science Monitor: International Medical Journal of Experimental and Clinical Research* 20: 78–82. <https://doi.org/10.12659/MSM.889659> [PubMed]
- Kawasaki R, Nagano E, Uno M, Okada M, Kawasaki Y, Kitamura A (2013) Retinal vascular features associated with risk of branch retinal vein occlusion. *Current Eye Research* 38(9): 989–993. <https://doi.org/10.3109/02713683.2013.798420> [PubMed]
- Lauver DA, Lucchesi BR (2006) Sulodexide: a renewed interest in this glycosaminoglycan. *Cardiovascular Drug Reviews* 24(3–4): 214–226. <https://doi.org/10.1111/j.1527-3466.2006.00214.x> [PubMed]

- Lu Q, Lu L, Chen W, Chen H, Xu X, Zheng Z (2015) RhoA/mDia-1/profilin-1 signaling targets microvascular endothelial dysfunction in diabetic retinopathy. *Graefe's Archive for Clinical and Experimental Ophthalmology* 253(5): 669–680. <https://doi.org/10.1007/s00417-015-2985-3> [PubMed]
- Ostrowski D, Heinrich R (2018) Alternative erythropoietin receptors in the nervous system. *Journal of Clinical Medicine* 7(2): E24. <https://doi.org/10.3390/jcm7020024> [PubMed]
- Peresyapkina AA (2018) Correction of ischemic optic neuropathy in rats by carbamylated darbepoetin. *Research Results in Pharmacology* 4(1): 43–50. <https://doi.org/10.3897/rrpharmacology.4.25262>
- Peresyapkina A, Dolzhikov A, Gubareva V, Levkova E, Shabelnikova A (2017) The development of hypertensive neuroretinopathy model on wistar rats. *Research Results in Pharmacology* 3(1): 18–31. <https://doi.org/10.18413/2500-235X-2017-3-1-18-31>
- Peresyapkina AA, Pokrovskii MV, Gubareva VO, Dolzhikov AA (2018) Protective effect of carbamylated darbepoetin on the model of ischemic neuropathy of the optic nerve in rats. *Experimental and Clinical Pharmacology [Eksperimental'naya i Klinicheskaya Farmakologiya]* 81(7): 8–13. <https://doi.org/10.30906/0869-2092-2018-81-7-8-13> [Google Scholar]
- Shabelnikova AS, Peresyapkina AA, Pokrovskii MV, Nikolaev SB, Shutov VI, Lutsenko VD, Shehegoleva TA, Philippenko NG, Reznikov KM, Sernov LN (2016) Pharmacological preconditioning by recombinant erythropoietin – a new way of treatment of retinal ischemia/reperfusion. *International Journal of Pharmacy and Technology* 8(4): 26889–96. [Google Scholar]
- Tyurenkov IN, Voronkov AV, Slietsans AA, Petrova EV, Snigur GL (2011) The study of effects of sulodexide on endothelium-dependent vasodilation of brain vessels in animals with streptozotocin-induced diabetes mellitus. *Diabetes Mellitus [Sakharnyi Diabet]* 52(3): 12–15. [in Russian]
- Tyurenkov IN, Voronkov AV, Slietsans AA, Snigur GL (2012) Effects of mexidol and sulodexide on the level of specific markers of endothelial dysfunction in animals with experimental diabetes mellitus. *Experimental and Clinical Pharmacology [Eksperimental'naya i Klinicheskaya Farmakologiya]* 75(5):14–16. <https://doi.org/10.30906/0869-2092-2012-75-5-14-16> [PubMed]
- Zahng L, Gu Y-h, An J, Zhang Z-m (2013) Effects of the duration of dark adaptation on the retinal function of normal SD rats. *Chinese Journal of Optometry Ophthalmology and Visual Science* 15(6): 323–326. [Google Scholar]

Author contributions

- **Victoria O. Gubareva**, Ophthalmologist of the Department of Pathology of Newborns and Premature Babies, St. Joseph Belgorod Regional Clinical Hospital, e-mail: vikaz@rambler.ru The author carried out experimental work, statistical data processing and evaluation of retinoprotective activity of pharmacological agents in the experiment.
- **Anton L. Pazhinsky**, Otorhinolaryngologist, Clinic of Ambulatory Surgery Plus, LLC, e-mail: bb_9393@mail.ru The author carried out the assessment of the comparative retinoprotective activity of the substances and data interpretation.
- **Sergey S. Lugovskoy**, Radiologist, Department of X-Ray Surgical Methods of Diagnosis and Treatment, St. Joseph Belgorod Regional Clinical Hospital, e-mail: lug90@mail.ru The author participated in the interpretation of histological research data.
- **Elizaveta Yu. Dubovtsova**, Ophthalmologist, Ophthalmology Department, City Hospital №2 of Belgorod, e-mail: lisisa007@bk.ru The author conducted electroretinography on laboratory rats.
- **Daria S. Vain**, Ophthalmologist, Children's Regional Clinical Hospital, e-mail: luci1993@mail.ru The author interpreted the data of LDF.
- **Anna S. Pobeda**, Candidate of Biological Sciences, PhD in Biology, Pharmacist, St. Joseph Belgorod Regional Clinical Hospital, e-mail: anny_87@mail.ru The author consulted on the idea and design of the study.
- **Konstantin N. Pasenov**, nurse, Oncohematology Department, Children's Regional Clinical Hospital, e-mail: luchik_svetasolnca@mail.ru The author carried out the registration of ocular blood flow in rats by LDF.